

# EBCT coronary calcium imaging for the early detection of coronary artery disease in asymptomatic individuals

D VIJAY ANAND, AVIJIT LAHIRI, DAVID LIPKIN

## Abstract

**C**oronary heart disease (CHD) is the leading cause of death in the UK. Approximately 50% of myocardial infarctions occur in patients with no prior history of CHD or cardiovascular risk factors while sudden death is often the first manifestation of CHD in as many as 35% of patients. The realisation that standard risk factors incompletely predict incident CHD events has led to the development of several non-invasive imaging techniques to accurately assess the risk of CHD over the last decade. Several epidemiological studies have established that the total coronary atherosclerotic plaque burden is a powerful predictor of future hard coronary events (myocardial infarction and death). This article reviews the role of electron beam computed tomography (EBCT) in the early detection of subclinical coronary artery disease, the identification of 'high-risk' asymptomatic patients for intensive medical intervention, and its role in evaluating the progression of coronary artery disease and in monitoring the efficacy of medical therapies.

**Key words:** coronary heart disease (CHD), electron beam computed tomography (EBCT), coronary artery calcification (CAC), atherosclerosis.

*Br J Cardiol* 2003;**10**:273–80

## Introduction

Coronary heart disease (CHD) is the leading cause of death in the UK and accounted for 125,000 deaths in the year 2000. Despite recent improvements, the death rate from CHD in the UK is amongst the highest in the world.<sup>1</sup> Hence accurate risk assessment

is assuming an increasing role in identifying high-risk individuals for intensive medical intervention to reduce the risk of CHD.

## Risk stratification in CHD – the role of conventional and emerging techniques

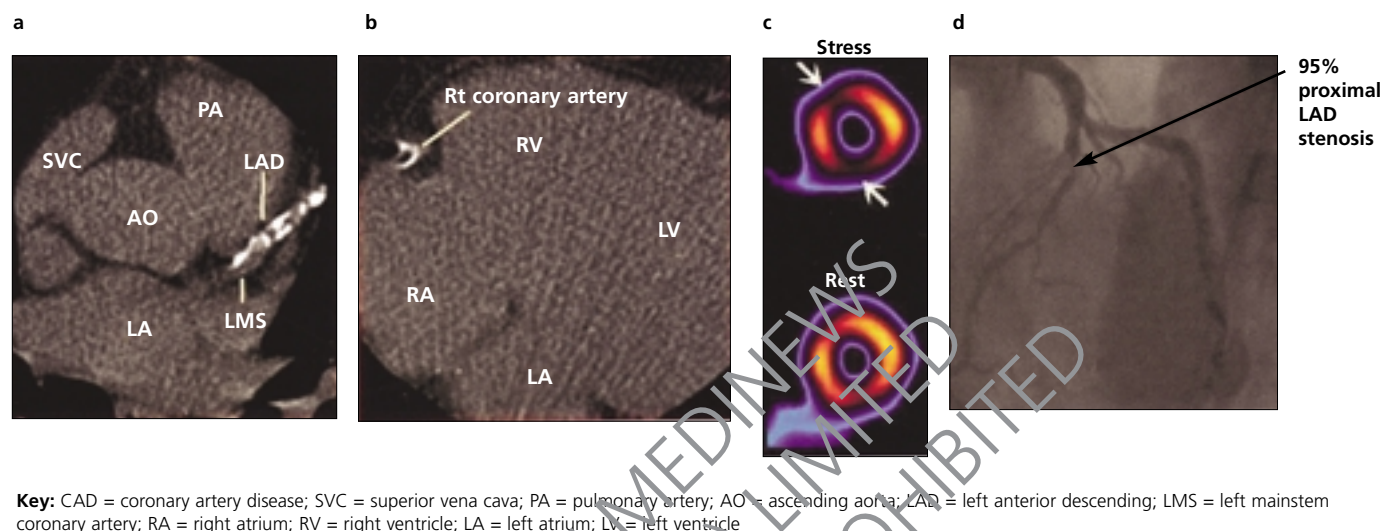
Approximately 50% of myocardial infarctions (MIs) occur in patients with no prior history of heart disease or risk factors. Sudden death is often the first manifestation of CHD in up to 35% of patients.<sup>2</sup> Since standard cardiovascular risk factors incompletely predict incident CHD events, alternative methods to predict the risk of CHD are required.<sup>3–5</sup> Recent investigations have shown that various markers of systemic inflammation can predict the risk of future CHD events in healthy men and women. These include high sensitivity C-reactive protein (CRP), fibrinogen, plasminogen activator inhibitor-1 (PAI-1), cytokines (e.g. IL-6 and TNF alpha), chemokines (e.g. monocyte chemoattractant protein-1 [MCP-1]), intercellular adhesion molecules (e.g. intercellular cellular adhesion molecule-1 [ICAM-1]), vascular cell adhesion molecule-1 (VCAM-1) and E-selectin. However, their role in everyday clinical practice remains to be established.<sup>6–9</sup>

It is well recognised that the majority of acute coronary syndromes (approximately 70%) occur from rupture of haemodynamically insignificant or non-obstructive coronary artery plaques representing a luminal stenosis of less than 50% diameter.<sup>2</sup> Furthermore, several epidemiological studies have shown that the total coronary atherosclerotic plaque burden is a better predictor of future hard coronary events (MI and death) than the site or severity of coronary luminal stenosis.<sup>10–13</sup>

Established non-invasive methods of evaluating coronary artery disease – such as exercise electrocardiography, radionuclide myocardial perfusion imaging and stress echocardiography – can detect lesions only when they limit coronary artery blood flow (> 50% luminal stenosis or more). They also cannot estimate the total coronary plaque burden. Although coronary angiography yields a high accuracy for the detection of haemodynamically significant stenoses, its sensitivity in demonstrating mild-to-moderate disease and in estimating total coronary plaque burden is inadequate.<sup>14,15</sup> Comparative studies of coronary angiography and intravascular ultrasound (IVUS) demonstrate the existence of significant atherosclerosis in angiographically normal coronary artery segments,<sup>14</sup> since vascular remodelling can compensate for luminal narrowing that occurs due to mild-to-moderate intimal plaques, by vessel enlargement.<sup>16</sup> Hence IVUS offers a distinct advantage over angiography for detection of atherosclerosis,

Cardiac Imaging and Research Centre, The Wellington Hospital, (South Building), Wellington Place, London, NW8 9LE.  
D Vijay Anand, Research Registrar in Cardiology (Northwick Park Hospital)  
Northwick Park Hospital, Watford Road, Harrow, HA1 3UJ.  
Avijit Lahiri, Honorary Consultant Cardiologist and Director of Cardiac Research  
Royal Free Hospital, Pond Street, London, NW3 2QG.  
David Lipkin, Consultant Cardiologist  
Correspondence to: Dr DV Anand  
(email: vdanand@hotmail.com)

**Figure 1.** A 31-year-old man with a positive family history of premature CAD was referred for cardiovascular assessment. He had borderline hypertension and a serum total cholesterol of 5.6 mmol/L with a low density lipoprotein cholesterol of 3.2 mmol/L. He was asymptomatic with a negative exercise tolerance test. **a)** and **b)** show the EBCT imaging, which revealed the presence of significant coronary calcification in all three coronary arteries with a CAC score (Agatston) of 1,180. Subsequent non-invasive evaluation for obstructive CAD with myocardial perfusion SPECT (Tc-99m sestamibi), seen in **c)**, showed significant reversible perfusion defects in the antero-septal and inferior walls (white arrow). **d)** shows the coronary angiogram which revealed a 95% proximal LAD artery and an eccentric 40% stenosis in the distal right coronary artery. He subsequently underwent PTCA/stenting of the proximal LAD artery in addition to aggressive medical management



especially in the early stages, and it is considered the reference standard for detection of atherosclerotic plaques.<sup>17</sup> Both coronary angiography and IVUS require invasive cardiac catheterisation, which is still associated with complications.

In the past decade, several imaging modalities have been utilised to assess the prognostic significance of atherosclerosis discovered non-invasively such as vascular ultrasonography, electron beam computed tomography (EBCT) (GE-Imatron, South San Francisco, California), multislice computed tomography (MSCT) and magnetic resonance imaging (MRI). This article will focus on the role of EBCT in the early detection of subclinical coronary artery disease and hence the identification of 'high-risk patients' for intensive medical intervention (figure 1).

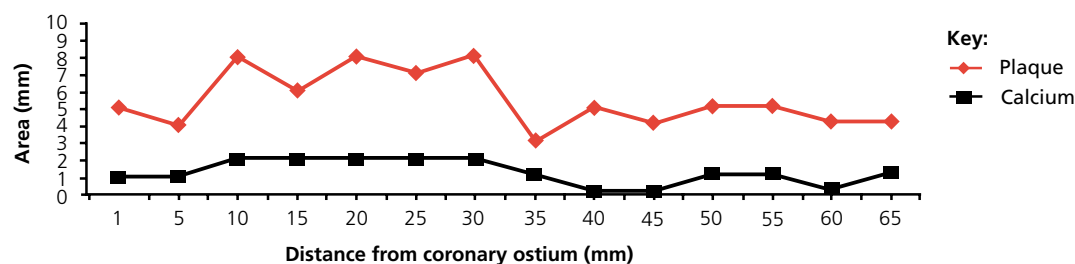
### Coronary calcium and atherosclerosis

Physicians recognised the association of calcified coronary arteries and the development of symptomatic coronary artery disease nearly 200 years ago.<sup>18</sup> In 1959 Blakenhorn defined the close relationship between coronary artery calcium and coronary atherosclerosis<sup>19</sup> (figure 2). Initial studies based on the fluoroscopic detection of coronary calcium were limited by marginal sensitivity and the inability to quantify the amount of coronary calcium. The introduction of EBCT as a new application of X-ray imaging in the mid 1980s led to a re-evaluation of coronary calcium as a marker for coronary atherosclerosis, due to its improved sensitivity for detecting vascular calcium and its inherent ability to quantify density and volume.<sup>20</sup>

### EBCT – the technology

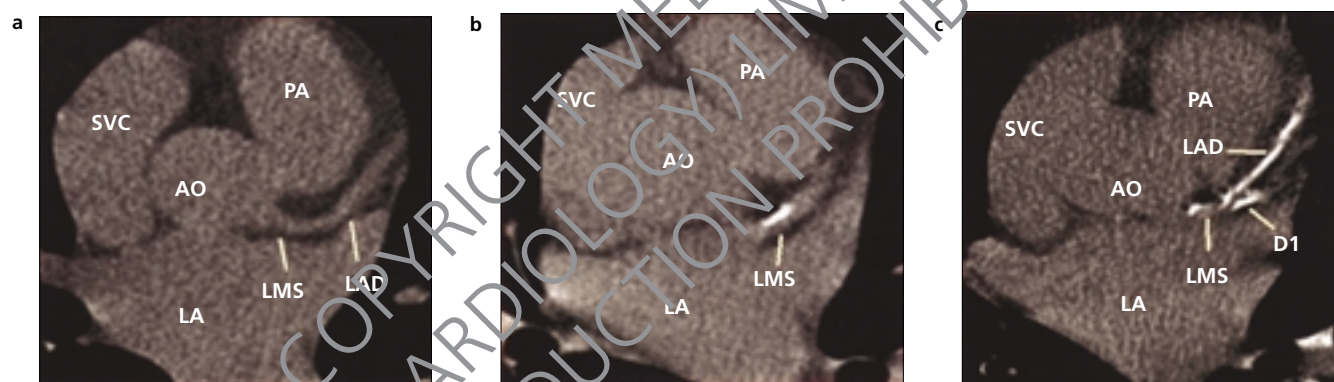
EBCT uses an electron gun and a stationary tungsten 'target' rather than a standard X-ray tube to generate X-rays, permitting very rapid scanning times. EBCT is well suited for the imaging of coronary arteries with its unique combination of three-dimensional capabilities (3-D), its high spatial (9 line pairs/cm) and temporal resolution (50 msec), and its ability to trigger image acquisition to the electrocardiogram, which virtually eliminates motion artifacts related to cardiac contraction. For the purposes of detecting coronary calcium, 30 to 40 serial transaxial images are obtained in 50–100 msec (the acquisition time for a single image), with a slice thickness of 3 mm during a single breath hold. The unopacified coronary arteries are easily identified by EBCT because the lower CT density of per-arterial fat produces a marked contrast to blood in the coronary arteries, while the mural calcium is evident because of its high CT density relative to blood. Examples of no, moderate and heavy proximal coronary calcification are illustrated in figure 3. The scanner software also allows quantification of coronary calcium area and density. Agatston and colleagues developed a calcium scoring algorithm based on the X-ray attenuation coefficient (or CT number measured in Hounsfield units) and the area of calcium deposits.<sup>21</sup> More recently Callister and associates have described an alternative method of determining EBCT calcium score, which has less variability and hence better reproducibility by quantifying the actual volume of coronary plaque (calcium volume score).<sup>22</sup>

**Figure 2.** Graph showing relationship between the extent of coronary calcification versus area of atherosclerotic plaque in 522 paired coronary artery segments



Adapted from: Simons DB *et al.* *J Am Coll Cardiol* 1992;20:1118-26

**Figure 3.** Single-level non-contrast EBCT scans performed at the base of the heart in three patients. Each scan illustrates the ascending aorta (AO), pulmonary artery (PA), superior vena cava (SVC), left atrium (LA), left mainstem coronary artery (LMS) and the proximal left anterior descending artery (LAD) with its diagonal branch (D1). Scan **a** did not reveal any coronary calcium, whereas scans **b** and **c** showed moderate and extensive coronary calcification respectively



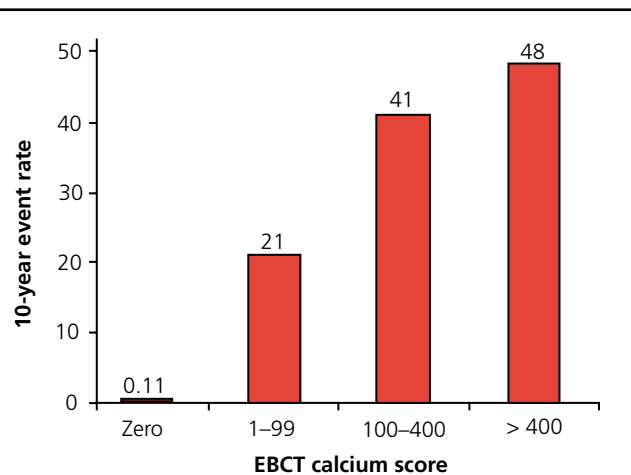
### Coronary calcium to assess coronary plaque burden

Coronary artery calcium is intimately associated with mural atheromatous plaque and is pathognomonic of atherosclerosis.<sup>23-25</sup> Clinical<sup>26-28</sup> and histopathological<sup>29-31</sup> studies confirm the close correlation between the extent of coronary artery calcification (CAC) and burden of atherosclerotic coronary disease. The total area and volume of coronary artery calcification, determined by EBCT, correlates in a linear fashion with the total area of coronary artery plaque on a segmental basis.<sup>32</sup> The EBCT coronary calcium score may not always predict the existence of significant luminal narrowing, but the sensitivity of EBCT to detect obstructive luminal disease increases with higher plaque burden (especially with an Agatston score of 400 or more).<sup>33-36</sup> A negative EBCT test (absence of coronary calcium) makes the presence of atherosclerotic plaque including unstable plaque very unlikely – this usually occurs in people with angiographically normal coronary arteries and is consistent with low risk of a cardiovascular event in the next two to five years.<sup>37</sup>

### Prognostic value of coronary artery calcification

The extent of CAC predicts the risk of future hard cardiovascular events in symptomatic patients and has a better prognostic value compared to coronary angiography.<sup>38,39</sup> Furthermore there is a direct relationship between increasing calcium scores and the occurrence of subsequent cardiac events (figure 4). Several prospective randomised trials have established the predictive value of CAC for future coronary events in asymptomatic individuals with varying risk factor profiles.<sup>40-46</sup> In a recent study, Raggi *et al.* demonstrated that a high calcium score ( $\geq 1,000$ ) on a screening EBCT in an asymptomatic person predicted a very high risk of hard cardiac events (death and MI) in the short term (25% per year)<sup>47</sup> (see figure 5). None of the 98 patients in the above study underwent either non-invasive or invasive testing, however, as a direct consequence of their EBCT scores. In the current climate it is unlikely that patients with such extensive plaque burden would be untreated and it will be interesting to

**Figure 4.** Bar chart showing coronary event rates based on calcium scores



Data from Raggi P *et al.*<sup>40</sup>

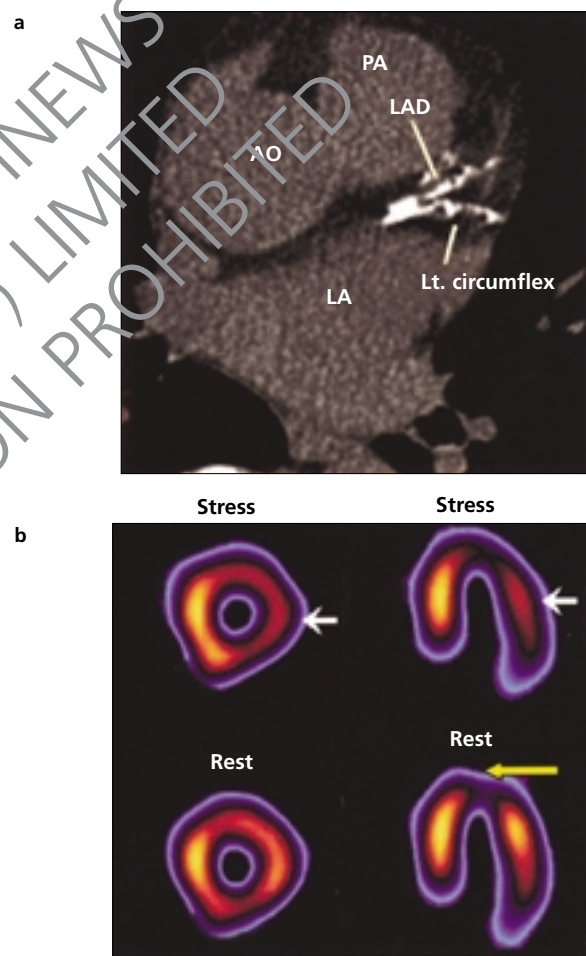
see whether EBCT could be used to monitor therapeutic success. Finally, the prognostic utility of CAC in risk stratifying patients with acute chest pain syndromes has also been shown.<sup>48-50</sup>

It is well known that patients with severe coronary stenoses can often be asymptomatic. In diabetic patients without cardiac symptoms or signs, but with other cardiovascular risk factors, silent myocardial ischaemia has been found in 10-30% of cases.<sup>51,52</sup> In a recent study of type 2 diabetic patients Rutter *et al.*<sup>53</sup> found that silent myocardial ischaemia was the strongest independent predictor of future CHD events. In a comparative study Schurgin *et al.* showed that patients with type 2 diabetes have a significantly higher prevalence of CAC scores > 400 (25.9%), consistent with a greater atherosclerotic plaque burden compared with randomly selected (7.2%) and matched non-diabetic (14.4%) control groups.<sup>54</sup> Adult end-stage renal disease patients on haemodialysis also have a higher prevalence of coronary calcification which is directly related to their increased risk of CHD.<sup>55</sup> This leads us to an important question. How should we evaluate asymptomatic patients with high calcium scores further? (see figures 1 and 5).

#### Evaluation of asymptomatic patients with high calcium scores

Mahmorian *et al.* showed that calcium scores greater than 400 have a strong correlation with the presence of reversible myocardial ischaemia on stress myocardial perfusion single-photon emission computed tomography (SPECT).<sup>56</sup> Myocardial perfusion imaging by SPECT and stress echocardiography are established non-invasive techniques to diagnose obstructive coronary artery disease that can also provide a functional assessment of the degree of myocardial ischaemia. Since it is well known that the extent, severity and reversibility of perfusion defects on SPECT imaging and the extent of inducible wall motion abnormalities

**Figure 5.** A 62-year-old man with treated hypertension and hyperlipidaemia was referred for cardiovascular risk assessment. He was asymptomatic with a negative exercise tolerance test. **a)** shows the EBCT image which revealed extensive triple vessel coronary calcification (Agatston score of 2,788). Further non-invasive evaluation for ischaemia with a Tc-99m sestamibi SPECT revealed, as seen in **b)**, a small apical infarct (yellow arrow) with extensive reversible ischaemia in the anterolateral and inferior walls (white arrow). Coronary angiography showed an eccentric 60% stenosis in the distal left mainstem coronary artery in addition to severe proximal stenoses in the left anterior descending artery, left circumflex vessel, obtuse marginal branch of left circumflex and a 40% stenosis in the distal right coronary artery with good left ventricular function. He subsequently underwent coronary artery bypass surgery in addition to institution of aggressive medical management



on stress echocardiography have a strong prognostic value,<sup>57-62</sup> a combined approach incorporating EBCT calcium scoring and SPECT imaging or stress echocardiography may be helpful in making a diagnosis, evaluating prognosis and monitoring the response to treatment in such patients. Alternatively, contrast-enhanced EBCT coronary angiography (EBA) is a promising tech-



nique for the non-invasive detection of coronary stenoses of prognostic importance. Electron beam CT angiography provides sensitivities and specificities greater than 90% for detecting high-grade coronary artery stenoses in the proximal and mid coronary artery segments<sup>63,64</sup> and is an excellent tool for evaluating coronary artery bypass graft patency (figure 6).

### Progression/regression trials – effect of lipid-lowering therapy on coronary calcium scores

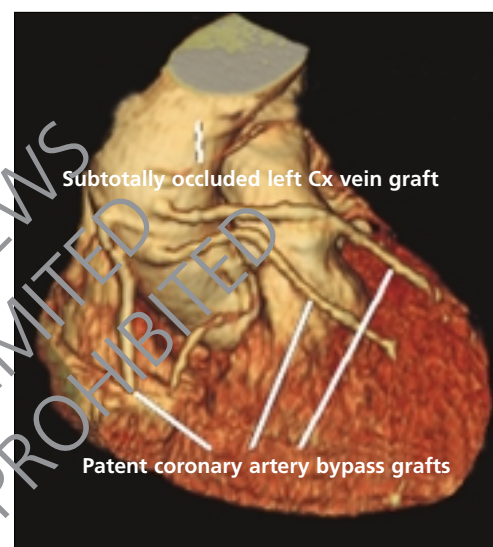
The prospect of using EBCT as a tool for monitoring therapy is exciting. With a low radiation burden in comparison to conventional CT scans<sup>65</sup> and a median interscan variability of 5% to 8%, EBCT can be effectively used to track progression of coronary atherosclerosis by periodically quantifying coronary calcium. Several progression studies, using two scans administered  $\geq$  one year apart, demonstrate significant annual progression (22% to 52% per year).<sup>66-68</sup> The annual coronary event rate for patients who demonstrate significant progression (increase in coronary artery calcium score  $> 20\%$  per year) is considerably greater than that for subjects with lesser rates of progression or even regression.<sup>69</sup> The extent to which the volume of atherosclerotic plaque decreased, stabilised or increased, on evaluation by EBCT, was directly related to treatment with HMG-CoA reductase inhibitors and the resulting serum LDL cholesterol levels.<sup>70</sup>

### Who should be screened by EBCT?

The Goldman criteria<sup>71</sup> for a diagnostic test in cardiology are as follows: it can be used 'to plan or monitor therapy, to establish a diagnosis, to define the extent of a known disease, to estimate prognosis, or to reassure the physician or the patient'. These criteria are consistent with the use of EBCT in specific clinical situations.<sup>72</sup> After evaluating the existing literature on EBCT coronary calcium imaging in 2000, The American College of Cardiology/American Heart Association joint task force on clinical expert consensus documents concluded that EBCT has a role in selected asymptomatic patients in whom standard risk assessment is considered insufficient.<sup>37</sup> Since age appears to be a surrogate marker for the total coronary atherosclerotic plaque burden, it has also been suggested that the coronary calcium score should replace age as a risk factor in Framingham scoring for CHD risk assessment.<sup>73</sup>

In our opinion EBCT coronary calcium imaging has an important role in the accurate risk stratification of asymptomatic patients with one or more conventional risk factors for coronary disease in whom clinical decision making regarding the need for medical intervention can often be uncertain. Currently the best example of this strategy is in regard to the decision of whether to institute cholesterol-lowering drug therapy. It is clear that not every asymptomatic adult with elevated cholesterol needs statin treatment nor can society afford it. Directing treatment based on standard risk factors appears not to be cost-effective.<sup>5</sup> Furthermore lack of conventional risk factors does not ensure absence of future coronary events. In such patients the detection of significant coronary atherosclerosis can provide a more compelling rationale for drug therapy of average or mild-to-moder-

**Figure 6.** Three-dimensional reconstruction of the heart, coronary arteries and bypass grafts obtained by contrast-enhanced EBCT in a 63-year-old man with vein grafts to the left anterior descending coronary artery (LAD), diagonal branch of LAD, left circumflex artery and right coronary artery. The study revealed patent vein grafts to the LAD, diagonal branch of LAD and right coronary artery. The saphenous vein graft to left circumflex (Cx) coronary artery was subtotally occluded. This was subsequently confirmed by invasive coronary angiography. Since the patient was symptomatic with exertional dyspnoea, PTCA/stenting to the left circumflex vein graft was performed



ately elevated lipid levels. The cost-effectiveness of an approach employing EBCT (using three different coronary calcium score [CAC] cut-offs – 37, 80 and 168) as the initial testing tool was superior to other non-invasive approaches, i.e. exercise testing, stress echocardiography and stress radionuclide imaging (thallium-201) as well as invasive approaches (direct coronary angiography) in individuals at low/moderate prevalence of obstructive coronary disease.<sup>74</sup>

### Conclusion

In conclusion, considerable evidence shows that coronary calcium is specific for atherosclerotic plaque and that it can be accurately detected and quantified by EBCT. Furthermore, the greater the EBCT calcium score, the greater the extent and severity of coronary atherosclerotic disease. There is little question that the presence of coronary calcium is predictive of future coronary events in an asymptomatic population. This technology also provides an opportunity to assess the progression of coronary artery disease non-invasively and monitor the clinical efficacy of medical therapies. Finally, by identifying high-risk patients, EBCT may help select those patients who would benefit most from additional testing (e.g. non-invasive stress imaging) and intensification of medical therapy. EBCT can have a significant impact on



### Key messages

- Approximately 50% of myocardial infarctions occur in patients with no prior history of CHD or standard cardiovascular risk factors
- The presence and extent of coronary calcification is a powerful predictor of hard coronary events (myocardial infarction, death)
- Electron beam computed tomography (EBCT) is an accurate non-invasive technique to quantify the extent of coronary calcification which strongly correlates with the total coronary atherosclerotic plaque burden
- EBCT imaging can identify a 'high-risk' group of asymptomatic individuals who would benefit from further non-invasive testing, aggressive risk factor modification and intensification of medical therapy
- EBCT can also be used to evaluate the progression of coronary artery disease and monitor the clinical efficacy of medical therapies

early detection and management of coronary artery disease in the UK population where the incidence of coronary artery disease is high.

### Acknowledgements

We thank Mr M McKenzie, Mr R Ruparelle, Ms R Joy and Ms R Oskam for their help and assistance in preparing this document.

### References

1. British Heart Foundation Health Promotion Research Group. Coronary heart disease statistics, *British Heart Foundation Statistics Database* 2002. www.bhf.org.uk
2. Falk E, Shah PK, Fuster V. Coronary plaque disruption. *Circulation* 1995; **92**:657-71.
3. Kannel WB, Neaton JD, Wentworth D *et al*. Overall and coronary heart disease mortality rates in relation to major risk factors in 325,348 men screened for the Multiple Risk Factor Intervention Trial (MRFIT). *Am Heart J* 1986; **112**:825-36.
4. Wald NJ, Law M, Watt HC, Wu T, Bailey A, Johnson AM. Apolipoproteins and ischaemic heart disease: implications for screening. *Lancet* 1994; **343**:75-9.
5. Grover SA, Coupal L, Hu XP. Identifying adults at increased risk of coronary disease: how well do the current cholesterol guidelines work? *JAMA* 1995; **274**:801-06.
6. Danesh J, Collins R, Appleby R, Peto R. Fibrinogen, C-reactive protein, albumin or white cell count: meta-analyses of prospective studies of coronary heart disease. *JAMA* 1998; **279**:477-82.
7. Ridker PM, Rifai N, Stampfer M, Hennekens CH. Plasma concentrations of interleukin -6 and the risk of future myocardial infarction among apparently healthy men. *Circulation* 2000; **101**:1767-72.
8. Hwang SJ, Ballantyne CM, Sharrett AR *et al*. Circulating adhesion molecules ICAM-1, VCAM-1 and E-selectin in carotid atherosclerosis and incident coronary heart disease cases: the Atherosclerosis Risk In Communities (ARIC) study. *Circulation* 1997; **96**:4219-25.
9. Hayden RM, Reaven PD. Cardiovascular disease in type II diabetes mellitus: a potential role for novel cardiovascular risk factors. *Curr Opin Lipidol* 2000; **11**:519-28.
10. Hasdai D, Bell MR, Grill DE. Outcome  $\geq$  10 years after successful percutaneous transluminal coronary angioplasty. *Am J Cardiol* 1997; **79**:1005-11.
11. Mock MB, Ringqvist I, Fisher LD. Survival of medically treated patients in the Coronary Artery Surgery Study registry (CASS). *Circulation* 1982; **66**:562-8.
12. Ambrose JA, Tannenbaum MA, Alexopoulos D. Angiographic progression of coronary artery disease and the development of myocardial infarction. *J Am Coll Cardiol* 1988; **12**:52-62.
13. Goldstein JA, Demetriou D, Grines CL, O'Neill WW. Multiple complex coronary plaques in patients with acute myocardial infarction. *N Engl J Med* 2000; **343**:915-22.
14. Mintz GS, Painter JA, Pichard AD. Atherosclerosis in angiographically 'normal' coronary artery reference segments: an intravascular ultrasound study with clinical correlation. *J Am Coll Cardiol* 1995; **25**:1479-85.
15. Topol EJ, Nissen SE. Our preoccupation with coronary luminology: the dissociation between clinical and angiographic findings in ischemic heart disease. *Circulation* 1995; **92**:2333-42.
16. Ge J, Erbel R, Zamorano J, Koch L, Meyer J. Coronary artery remodelling in atherosclerotic disease: an intravascular study *in vivo*. *Coronary Artery Dis* 1993; **4**:981-6.
17. Waller BF, Pinkerton CA, Slack JD. Intravascular ultrasound; a histologic study of vessels during life. The new 'gold standard' for vascular imaging. *Circulation* 1992; **85**:305-10.
18. Parry G. In: *Inquiry into the symptoms and causes of syncopa anginosa, commonly called angina pectoris*. 1799.
19. Blakenhorn DH, Stern L. Calcification of coronary arteries. *Am J Roentgen* 1959; **81**:772-7.
20. Tannenbaum SR, Kondos GT, Veselik KE, Pendergast M, Brundage BH, Chomka EV. Detection of calcific deposits in coronary arteries by ultrafast computed tomography and correlation with angiography. *Am J Cardiol* 1989; **63**:870-2.
21. Agatston AS, Janowitz WR, Hildner FJ, Zusmer NR, Viamonte MJ, Detrano R. Quantification of coronary artery calcium using ultrafast computed tomography. *J Am Coll Cardiol* 1990; **15**:827-32.
22. Callister TQ, Cooil B, Raya SP, Lippolis NJ, Russo DJ, Raggi P. Coronary artery disease: improved reproducibility of calcium scoring with an electron beam CT volumetric method. *Radiology* 1998; **208**:807-14.
23. Frink RJ, Achor RW, Brown AL. Significance of calcification of the coronary arteries. *Am J Cardiol* 1970; **26**:241-7.
24. McCarthy JH, Palmer FJ. Incidence and significance of coronary artery calcification. *Br Heart J* 1974; **36**:499-506.
25. Rifkin RD, Parisi AF, Folland E. Coronary calcification in the diagnosis of coronary artery disease. *Am J Cardiol* 1979; **44**:141-7.
26. Schmermund A, Baumgart D, George G. Coronary artery calcium in acute coronary syndromes: a comparative study of electron-beam computed tomography, coronary angiography, and intracoronary ultrasound in survivors of acute myocardial infarction and unstable angina. *Circulation* 1997; **96**:1461-9.
27. Mintz GS, Pichard AD, Popma JJ. Determinants and correlates of target calcium lesion in coronary artery disease: a clinical, angiographic and intravascular ultrasound study. *J Am Coll Cardiol* 1997; **29**:268-74.
28. Baumgart D, Schmermund A, George G. Comparison of electron beam computed tomography with intracoronary ultrasound and coronary angiography for detection of coronary atherosclerosis. *J Am Coll Cardiol* 1997; **30**:57-64.
29. Rumberger JA, Simons B, Fitzpatrick L, Schwartz RS. Coronary artery calcium area by electron-beam computed tomography and coronary atherosclerotic plaque area: a histopathologic correlative study. *Circulation* 1995; **92**:2157-62.
30. Sanigorgi G, Rumberger JA, Severson A. Arterial calcification and not lumen stenosis is significantly correlated with atherosclerotic plaque burden in humans: a histologic study of 723 coronary artery segments using non-decalcifying methodology. *J Am Coll Cardiol* 1998; **31**:126-33.
31. Mautner SL, Mautner GC, Froelich J. Coronary artery disease: prediction with *in vitro* electron-beam CT. *Radiology* 1994; **192**:625-30.
32. Rumberger JA, Simons DB, Fitzpatrick LA. Coronary artery calcium area by electron beam computed tomography and coronary atherosclerotic plaque area: a histopathologic correlative study. *Circulation* 1995; **92**:2157-62.

33. Breen JF, Sheedy PF II, Schwartz RS, Stanson AW, Kaufmann RB, Moll PP. Coronary artery calcification detected with ultrafast CT as an indication of coronary artery disease. *Radiology* 1992;**185**:435-9.
34. Schmermund A, Baumgart D, Gorge G, Seibel R, Gronemeyer D, Ge J. Coronary artery calcium in acute coronary syndromes: a comparative study of electron beam computed tomography, coronary angiography and intracoronary ultrasound in survivors of acute myocardial infarction and unstable angina. *Circulation* 1997;**96**:1461-9.
35. Bielak LF, Rumberger JA, Sheedy PF. Probabilistic model for prediction of angiographically defined obstructive coronary artery disease using electron beam computed tomography score strata. *Circulation* 2000;**102**:380-5.
36. Nallamothu BK, Saint S, Bielak LF *et al.* Electron beam computed tomography in the diagnosis of coronary artery disease: a meta-analysis. *Arch Intern Med* 2001;**161**:833-8.
37. The American College of Cardiology/American Heart Association expert consensus document on electron beam computed tomography for the diagnosis and prognosis of coronary artery disease. *J Am Coll Cardiol* 2000;**36**:326-40.
38. Keelan PC, Bielak LF, Ashai K *et al.* Long-term prognostic value of coronary calcification detected by electron beam computed tomography in patients undergoing coronary angiography. *Circulation* 2001;**104**:412-17.
39. Detrano R, Hsiai T, Wang S *et al.* Prognostic value of coronary calcification and angiographic stenoses in patients undergoing coronary angiography. *J Am Coll Cardiol* 1996;**27**:285-90.
40. Raggi P, Callister TQ, Cooil B *et al.* Identification of patients at increased risk of first unheralded acute myocardial infarction by electron beam computed tomography. *Circulation* 2000;**101**:850-5.
41. Detrano RC, Wong ND, Doherty TM, Shavelle R. Prognostic significance of coronary calcific deposits in asymptomatic high-risk subjects. *Am J Med* 1997;**102**:344-9.
42. O'Malley PG, Taylor AJ, Jaccson JL *et al.* Prognostic value of coronary electron beam computed tomography for coronary heart disease events in asymptomatic populations. *Am J Cardiol* 2000;**85**:945-8.
43. Detrano RC, Wong ND, Doherty TM *et al.* Determining coronary event risk in asymptomatic high risk subjects: a risk factor vs. an anatomic approach. *Circulation* 1999;**99**:2633-8.
44. Arad Y, Spadaro LA, Goodman K *et al.* Predictive value of electron beam computed tomography of the coronary arteries: 19 month follow-up of 1,173 asymptomatic subjects. *Circulation* 1996;**93**:195-3.
45. Seci A, Wong N, Tang W, Wang S, Doherty T, Detrano R. Electron beam computed tomographic coronary calcium as a predictor of coronary events: a comparison of two protocols. *Circulation* 1997;**96**:1122-9.
46. Raggi P, Cooil B, Callister TQ. Use of electron beam tomography data to develop models for prediction of hard coronary events. *Am Heart J* 2001;**141**:375-82.
47. Wayhs R, Zellinger A, Raggi P. High coronary artery calcium scores pose an extremely elevated risk for hard events. *J Am Coll Cardiol* 2002;**39**:225-30.
48. Georgiou D, Budoff MJ, Kaufer E, Kennedy JM, Lu B, Brundage BH. Screening patients with chest pain in the emergency department using electron beam tomography: a follow-up study. *J Am Coll Cardiol* 2001;**38**(1):105-10.
49. McLaughlin VV, Balogh T, Rich S. Utility of electron beam computed tomography to stratify patients presenting to the emergency room with chest pain. *Am J Cardiol* 1999;**84**:327-8.
50. Laudon DA, Vukov LF, Breen JF, Rumberger JA, Wollan PC, Sheedy PF II. Use of electron beam computed tomography in the evaluation of chest pain patients in the emergency department. *Ann Emerg Med* 1999;**33**(1):15-21.
51. Chiariello M, Indolfi C. Silent myocardial ischemia in patients with diabetes mellitus. *Circulation* 1996;**93**:2089-91.
52. Nesto RW, Phillips RT, Kett KG *et al.* Angina and exertional myocardial ischemia in diabetic and nondiabetic patients: assessment by exercise thallium scintigraphy. *Ann Intern Med* 1988;**108**:170-5.
53. Rutter MK, Wahid ST, McComb JM, Marshall SM. Significance of silent ischemia and microalbuminuria in predicting coronary events in asymptomatic patients with type 2 diabetes. *J Am Coll Cardiol* 2002;**40**(1):56-61.
54. Schurgin S, Rich S, Mazzone T. Increased prevalence of significant coronary artery calcification in patients with diabetes. *Diabetes Care* 2001;**24**:335-8.
55. Raggi P, Boulay A, Chertow GM. Cardiac calcification in adult hemodialysis patients. A link between end-stage renal disease and cardiovascular disease? *J Am Coll Cardiol* 2002;**39**:695-701.
56. He ZX, Hedrick TD, Pratt CM *et al.* Severity of coronary artery calcification by electron beam computed tomography predicts silent myocardial ischemia. *Circulation* 2000;**101**:244-51.
57. Brown KA. Prognostic value of thallium-201 myocardial perfusion imaging. A diagnostic tool comes of age. *Circulation* 1991;**83**:363-81.
58. Hachamovitch R, Berman DS, Kiat H. Exercise myocardial perfusion SPECT in patients without known coronary artery disease: incremental prognostic value and use in risk stratification. *Circulation* 1996;**93**:905-14.
59. Hachamovitch R, Berman DS, Shaw LJ. Incremental prognostic value of myocardial perfusion single photon emission computed tomography for the prediction of cardiac death: differential stratification for risk of cardiac death and myocardial infarction. *Circulation* 1998;**97**:535-43.
60. Sharir T, Germano G, Kavanagh PB. Incremental prognostic value of post-stress left ventricular ejection fraction and volume by gated myocardial perfusion single photon emission computed tomography. *Circulation* 1999;**100**:1035-42.
61. Chah SC, Pelikka PA, Roger VL, McCully RB, Seward JB. Role of dobutamine stress echocardiography in predicting outcome of 860 patients with known or suspected coronary artery disease. *Circulation* 1998;**97**:1474-80.
62. Malcowitz PA, Armstrong WF. Accuracy of dobutamine stress echocardiography in detecting coronary artery disease. *Am J Cardiol* 1992;**69**:1269-73.
63. Achenbach SA, Moshage W, Ropers D, Daniel WG. Value of electron-beam computed tomography for the detection of high-grade coronary artery stenoses and occlusions. *N Engl J Med* 1998;**339**:1964-71.
64. Schmermund A, Rensing BJ, Sheedy PF, Bell MR, Rumberger JA. Intravenous electron beam computed tomographic coronary angiography for segmental analysis of coronary artery stenoses. *J Am Coll Cardiol* 1998;**31**:1547-54.
65. McCollough CH, Zink FE, Morin RL. Radiation dosimetry for electron beam CT. *Radiology* 1994;**192**:637-42.
66. Budoff MJ, Lane KL, Bakhsheshi H *et al.* Rates of progression of coronary calcification by electron beam tomography. *Am J Cardiol* 2000;**86**:8-11.
67. Mahler JE, Bielak LF, Raz JA, Sheedy PF, Schwartz RS, Peyser PA. Progression of coronary artery calcification: a pilot study. *Mayo Clin Proc* 1999;**74**:347-55.
68. Janowitz WR, Agatston AS, Viamonte M. Comparison of serial quantitative evaluation of calcified coronary artery plaque by ultrafast computed tomography in persons with and without obstructive coronary artery disease. *Am J Cardiol* 1991;**68**:1-6.
69. Shah AS, Sorochinsky B, Mao SS, Naik TK, Budoff MJ. Cardiac events and progression of coronary calcium score using electron beam tomography (abstract). *Circulation* 2000;**102**(suppl II):604.
70. Callister TQ, Raggi P, Cooil B, Lippolis N, Russo DJ. Effect of HMG-CoA reductase inhibitors on coronary artery disease as assessed by electron beam computed tomography. *N Engl J Med* 1998;**339**:1972-8.
71. Goldman L. Cost-effective strategies in cardiology. In: Braunwald E (ed.). *Heart disease: a textbook of cardiovascular medicine*. 6th edn. Philadelphia: Saunders, 2001;1694-707.
72. Rumberger JA, Brundage BH, Rader DJ, Kondos G. Electron beam computed tomographic coronary calcium scanning: a review and guidelines for use in asymptomatic persons. *Mayo Clin Proc* 1999;**74**:243-52.
73. Grundy SM. Coronary plaque as a replacement for age as a risk factor in global risk assessment. *Am J Cardiol* 2001;**88**(suppl 2A):8E-11E.
74. Rumberger JA, Behrenbeck T, Breen JF, Sheedy PF. Coronary calcification by electron beam computed tomography and obstructive coronary artery disease: a model for costs and effectiveness of diagnosis as compared with conventional cardiac testing methods. *J Am Coll Cardiol* 1999;**33**:453-62.