

# Echocardiography is not indicated for an enlarged cardiothoracic ratio

Lucinda Wingate-Saul, Yassir Javaid, John Chambers

## Authors

**Lucinda Wingate-Saul**  
MBBS Student, Kings College  
London

**John Chambers**  
Professor of Clinical Cardiology  
St Thomas' Hospital, London,  
SE1 7EH

**Yassir Javaid**  
GPwSI Cardiology

Danes Camp Surgery, Rowtree  
Road, East Hunsbury,  
Northampton NN4 0NY

**Correspondence to:**  
Ms L Wingate-Saul  
([lucinda.wingate-saul@kcl.ac.uk](mailto:lucinda.wingate-saul@kcl.ac.uk))

## Key words

echocardiography, general  
practice, heart failure, X-ray

First published online November  
12th 2013

doi: 10.5837/bjc.2013.30

*Br J Cardiol* 2013;20:149–50

**A**n increased cardiothoracic ratio (CTR) on chest X-rays is a not uncommon reason for requesting echocardiography. To assess how often the echocardiogram was abnormal in patients with an increased CTR, the results of 62 open-access echocardiograms requested with this indication were analysed.

Means, standard deviations and 95% confidence intervals were calculated for the left ventricular diameters of the patient group investigated. Two-tailed *t*-tests were used to compare those with and without reported breathlessness, and those with additional radiology consistent with heart failure. Positive predictive values (PPVs) were calculated.

Only four echocardiograms were abnormal, giving a PPV for CTR of 6%. This increased only slightly to 15% with the inclusion of another radiological abnormality, and to 19% with a symptom or sign. We, therefore, conclude that an increased CTR alone is not a valid reason for requesting echocardiography.

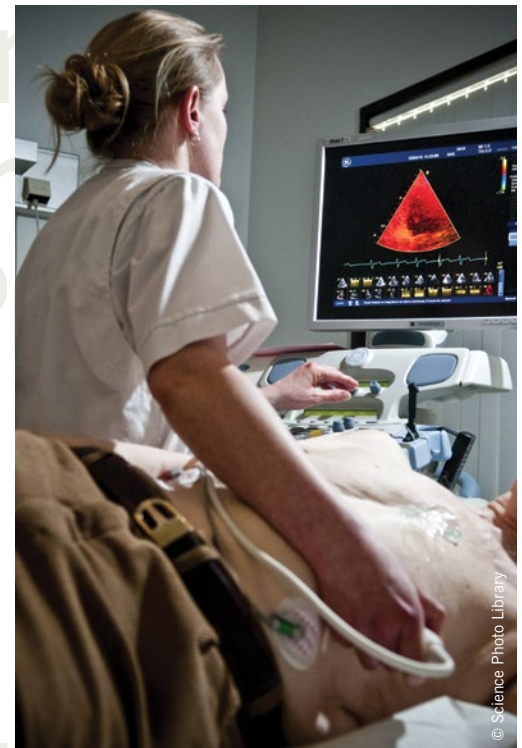
## Introduction

National Institute for Health and Care Excellence (NICE) guidance for the investigation of breathlessness is to request echocardiography if either the 12-lead electrocardiogram (ECG) is abnormal or the B-type natriuretic peptide (BNP) level raised.<sup>1</sup> Heart size judged by the chest X-ray is not part of this screening process and known not to correlate well with left ventricular (LV) systolic dysfunction.<sup>2–3</sup> Nevertheless, an increased cardiothoracic ratio (CTR) on a chest X-ray is a not uncommon reason for requesting echocardiography.

We, therefore, assessed the results of open-access echocardiography performed because of an increased CTR.

## Materials and methods

We examined the reports of 62 open-access studies performed between September 2009



and November 2012 at Guy's and St Thomas Hospitals. All gave 'enlarged CTR' as the reason for referral. The echocardiograms were reported as abnormal based on conventional clinical criteria, predominantly LV linear dimensions and estimated ejection fraction.

Results were analysed separately for those with and without breathlessness. They were also analysed separately for those with and without radiographic signs consistent with raised left heart filling pressures (venous congestion, interstitial oedema). Mean, standard deviation (SD) and 95% confidence intervals (CIs) were calculated. The groups were compared using a two-tailed *t*-test. Positive predictive values (PPVs) were calculated.

## Results

The 62 patients had a mean age of 60 (range 24–82) years and 23 were male and 39 female.

## ECHOCARDIOGRAPHY

The CTR value was provided in 17 cases and had a mean 0.58 (range 0.53–0.67). Associated radiological findings were included in 13 requests (pulmonary venous hypertension, fluid overload and sternotomy wires suggesting previous heart surgery). Symptoms or clinical signs were noted in 21 requests (atrial fibrillation, oedema, dyspnoea, shortness of breath on exertion and cough). In addition, 23 patients were noted to be hypertensive, although it was not mandatory for this to be included in the referral.

The mean LV end systolic diameter (LVESd) for all patients was 3.1 cm (SD 0.85 cm, 95% CI 0.21 cm), and the mean LV end diastolic diameter (LVEDd) was 4.7 cm (SD 0.69 cm, 95% CI 0.17 cm). There were no statistically significant differences comparing patients with and without abnormal radiological features or with and without clinical signs or symptoms.

Only four (6%) echocardiograms were abnormal. Of these, two had additional radiological features, and all had symptoms consistent with heart failure. They had significantly larger LVESd (5.4 cm, SD 0.52 cm;  $p=0.002$ ) and LVEDd (6.3 cm, SD 0.47 cm;  $p=0.006$ ) than the rest.

The PPV of an increased CTR for an abnormal echocardiogram was only 6%

and this increased slightly to 15% with the inclusion of another radiological abnormality and to 19% with a symptom or sign. No patients with normal CTR were studied to calculate specificity or negative predictive values.

## Discussion

This study showed that 94% of echocardiograms performed because of an increased CTR, were normal. The PPV of 6% increased only slightly if an additional radiological sign or a symptom or sign consistent with heart failure were included to narrow the criteria for performing an echocardiogram.

While the population size is relatively small, and the mean sample age is relatively young, it represents a real-life clinical series of consecutive cases with objective measures of LV size and function.

A CTR  $>0.5$  is considered to be possibly enlarged and a CTR  $\geq 0.55$  to be unequivocally enlarged.<sup>4</sup> Of 17 CTRs provided in the open-access referrals, 12 met the criteria for unequivocal enlargement. These results confirm the European Society of Cardiology guidelines that chest radiography is useful to screen for certain lung diseases, but not for the diagnosis of

heart failure,<sup>5</sup> which may occur despite a normal CTR.<sup>4</sup>

An increased CTR alone is not a valid reason for requesting echocardiography ●

## Conflict of interest

None declared.

## Key messages

- Open-access echocardiography is an important resource in primary care, but in order for its use to be efficient, adherence to specific referral indicators is encouraged
- Enlarged cardiothoracic ratio (CTR) has been shown to be an unreliable indicator of heart failure, but remains a common reason for referrals, especially if there are suggestive signs and symptoms
- This study found a positive predictive value of only 6% for heart failure using enlarged CTR, reinforcing the message that it is not a valid reason for requesting echocardiography, even with signs or symptoms consistent with heart failure

## References

1. National Institute for Health and Care Excellence. Chronic heart failure: National clinical guideline for diagnosis and management in primary and secondary care. London: NICE, 2010. Available from: <http://www.nice.org.uk/nicemedia/>

live/13099/50514/50514.pdf [accessed 20/02/13].

2. Fonseca C, Mota T, Morais H *et al.* The value of the electrocardiogram and chest x-ray for confirming or refuting suspected diagnosis of heart failure in the community. *Eur J Heart Fail* 2004;**6**:807–12. <http://dx.doi.org/10.1016/j.ejheart.2004.09.004>

3. Clark AL, Coats AS. Unreliability of cardiothoracic ratio as a marker of left ventricular impairment: comparison with radionuclide ventriculography and echocardiography. *Postgrad Med J* 2000;**76**:289–91. <http://dx.doi.org/10.1136/pmj.76.895.289>

4. Petrie MC. It cannot be cardiac failure if the heart is not enlarged on the chest

x-ray. *Eur J Heart Fail* 2003;**5**:117–19. [http://dx.doi.org/10.1016/S1388-9842\(02\)00239-8](http://dx.doi.org/10.1016/S1388-9842(02)00239-8)

5. McMurray JJV, Adamopoulos A, Anker SD *et al.* ESC guidelines for the diagnosis and treatment of acute and chronic heart failure 2012. *Eur Heart J* 2012;**33**:1787–847. <http://dx.doi.org/10.1093/eurheartj/ehs104>

Interested in cardiac rhythm management? For latest news and views log on to our sister website:

[www.arwatch.co.uk](http://www.arwatch.co.uk)

