Echocardiographic Assessment of Pulmonary Hypertension

Standard Operating Procedure

The development, printing and production of the Echocardiographic Assessment of Pulmonary Hypertension Standard Operating Procedure was supported by Actelion. Actelion had no influence on content

Address for correspondence:

Dr Luke Howard
National Pulmonary Hypertension Service (London)
Department of Cardiac Sciences
Hammersmith Hospital
Imperial College Healthcare NHS Trust
Du Cane Road
London W12 0HS

l.howard@imperial.ac.uk
Tel: +44 20 8383 2330
Fax: +44 20 8383 2331

Supported by:

British Society of Echocardiography
Affiliated to the British Cardiac Society

The development, printing and production of the Echocardiographic Assessment of Pulmonary Hypertension Standard Operating Procedure was supported by Actelion.

Actelion had no influence on content

ACTELION

©Copyright Imperial College Healthcare NHS Trust 2010

Date of prep November 2010
ACT 10/1574

Table of Contents

Protocol Working Group 4
Introduction 6
Right Ventricular Anatomy 9
Right Ventricular Pathophysiology 9
Right Ventricular Measurements 11
Pulmonary Hypertension/ Right Heart Imaging Protocol 12
Protocol In-Depth 13
- Parasternal Long Axis View of the Left Ventricle 13
- Parasternal Long Axis View of Right Ventricular Inflow Tract 15
- Parasternal Long and Short Axis Views of the Right Ventricular Outflow Tract 17
- Parasternal Short Axis View of Aorta and Left Atrium 19
- Short Axis View at the Level of Left Ventricular Papillary Muscles 20
- Apical Four-Chamber View 22
- Apical Five-Chamber View 26
- Subcostal View 26
- Indexing for Heart Rate 28
- Indexing for Body Surface Area 28

Right Ventricular Pressure *versus* Volume-Loading 29
Qualitative Assessment of the Right Ventricle 30
- Dilatation 30
- Hypertrophy 31
- Contractility 32

Pressure Measurements 33
- Right Atrial Pressure 33
- Right Ventricular Systolic Pressure (Tricuspid Regurgitant Velocity) 34
- Pulmonary Artery Mean and Diastolic Pressure 36
- Right Ventricular Outflow Tract Acceleration Time 38

Cavity Measurements (2D) 39
- Measurement of RA volume index 39
- Right Ventricular Fractional Area Change 40
- Left Ventricular Eccentricity index 40

Tissue Doppler imaging (TDI) 43
- Right Ventricular Diastolic Dysfunction 43

Measures of Function 44
- Myocardial Performance Index of the Right Ventricle (RV MPI) 44
- S' wave velocity 46
- Isovolumic Relaxation Time (IVRT) 46
- Tricuspid Annular Plane Systolic Excursion (TAPSE) 47
- Stroke volume, Cardiac Output and Pulmonary Vascular Resistance 48
- Haemodynamics & Vasoreactivity 49

Assessing Prognosis and Clinical Course in Pulmonary Hypertension 50
Assessment of PulmonaryHypertension in Children 52
Echocardiography Reporting 58
Sample reports 60
References 64

Protocol Working Group

Dr Julia Grapsa

Research Fellow (funded by Actelion and European Society of Cardiology)

Dept of Echocardiography

Imperial College Healthcare NHS Trust

Mr David Dawson

Chief Echocardiographer

Dept of Echocardiography

Imperial College Healthcare NHS Trust

Dr Michael Bellamy

Consultant Cardiologist

Dept of Echocardiography

Imperial College Healthcare NHS Trust

Professor Petros Nihoyannopoulos

Head of Echocardiography

Dept of Echocardiography

Imperial College Healthcare NHS Trust

Dr Simon Gibbs

Consultant Cardiologist

Hammersmith Hospital

Imperial College Healthcare NHS Trust

Dr Luke Howard

Consultant Chest Physician

Hammersmith Hospital

Imperial College Healthcare NHS Trust

Dr Ingram Schulze-Neick

Consultant Paediatric Cardiologist

Great Ormond Street Hospital

External Reviewers

Professor John Chambers

Consultant Cardiologist

Guy's & St Thomas's Hospital, London

Dr Navroz Masani

President

British Society of Echocardiography

Consultant Cardiologist

Univeristy Hospital of Wales, Cardiff

Review Group

Dr Gerry Coghlan

Consultant Cardiologist, Lead Clinician, Pulmonary Hypertension Service, Royal Free Hospital

Prof Paul Corris

Professor of Respiratory Medicine, Lead Clinician, Pulmonary Vascular Unit, Freeman Hospital

Dr Sean Gaine

Consultant Chest Physician, Lead Clinician, Pulmonary Hypertension Service, Mater Misericordiae University Hospital

Dr Antionette Kenny

Consultant Cardiologist, Freeman Hospital

Dr David Kiely

Consultant Chest Physician, Lead Clinician, Pulmonary Vascular Unit, Royal Hallamshire Hospital

Dr Laurence O'Toole

Consultant Cardiologist, Royal Hallamshire Hospital

Prof Andrew Peacock

Professor of Respiratory Medicine, Lead Clinician, Scottish Pulmonary Vascular Unit Golden Jubilee National Hospital

Dr Joanna Pepke-Zaba

Consultant Chest Physician, Lead Clinician, Pulmonary Vascular Diseases Unit, Papworth Hospital NHS Trust

Dr Piotr Sonecki

Consultant Cardiologist, Golden Jubilee National Hospital

Dr John Wort

Consultant Chest Physician, Lead Clinician, Pulmonary Hypertension Centre, Royal Brompton

Introduction

In this booklet, we describe an echocardiographic protocol for patients with chronic pulmonary hypertension. It is assumed that the minimum standards for echocardiography laid out by the British Society of Echocardiography (BSE) will be adhered to when undertaking echocardiography.

Many of the measurements we describe here for the identification of pulmonary hypertension and assessment of right ventricular function are part of the minimum dataset recommended by the BSE or can be obtained from views which are part of the basic protocol.

1. Pulmonary Arterial Hypertension (PAH)

- Idiopathic PAH
- Heritable PAH
- Drugs or toxins-induced
- Persistent Pulmonary Hypertension of the Newborn
- Associated with:
  - Connective tissue disease
  - HIV
  - Portal Hypertension
  - Congenital heart disease
  - Schistosomiasis
  - Chronic haemolytic anaemia

1'. Pulmonary Veno-occlusive Disease and/or Pulmonary Capillary Haemangiomatosis

2. Pulmonary Hypertension due to left heart disease

Systolic dysfunction
Diastolic dysfunction
Valvular disease

3. Pulmonary Hypertension due to lung disease and/or hypoxaemia

4. Chronic Thromboembolic Pulmonary Hypertension

5. Pulmonary Hypertension with unclear and/or multifactorial mechanisms

Table 1. Classification of Pulmonary Hypertension

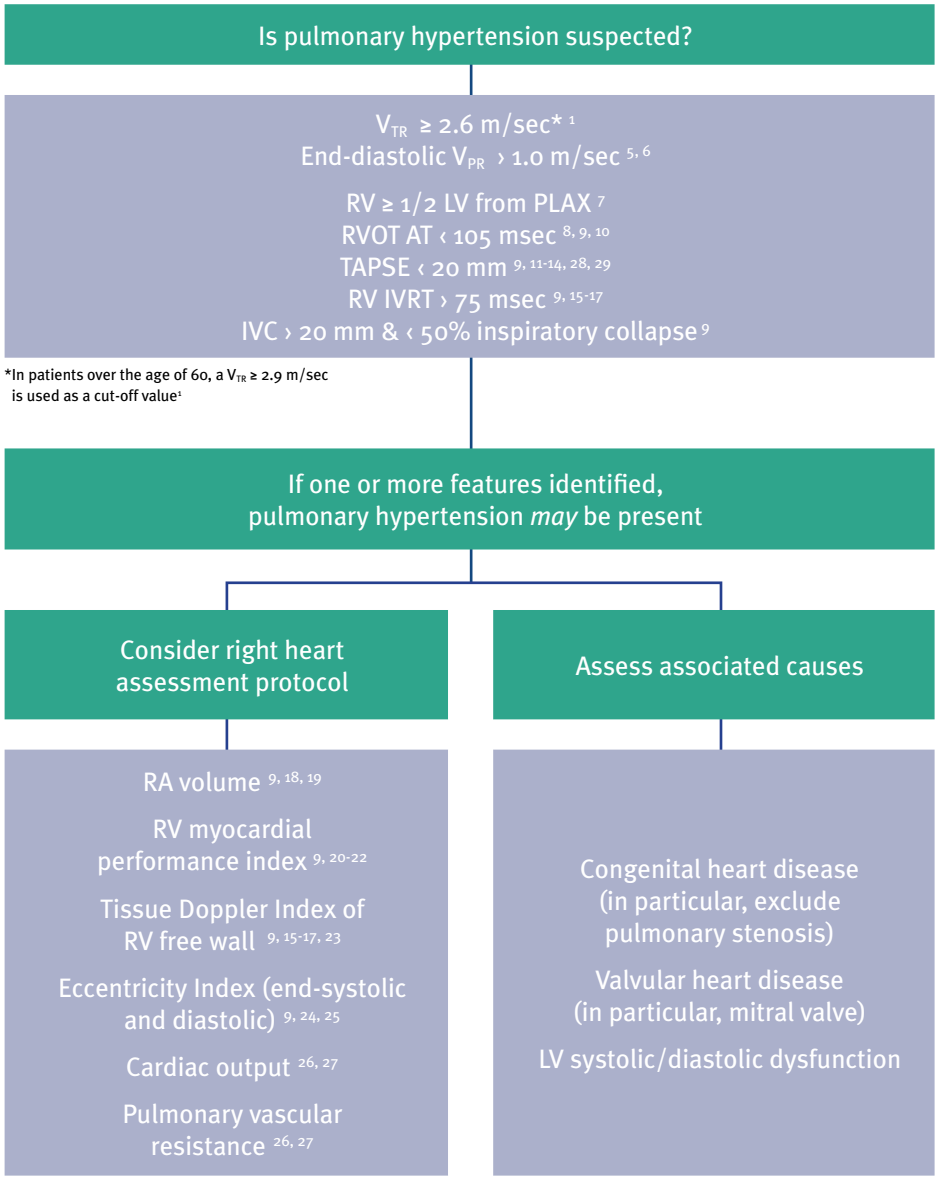

Figure 1. Algorithm for investigating pulmonary hypertension using transthoracic echocardiography. AT, acceleration time; IVC, inferior vena cava; IVRT, isovolumic relaxation time; LV, left ventricle; PAP, pulmonary artery pressure; PLAX, parasternal long axis; RA, right atrium; RV, right ventricle; RVSP, right ventricular systolic pressure; RVOT, right ventricular outflow tract; TAPSE, tricuspid annular plane systolic excursion; V_{PR}, pulmonary regurgitant velocity; V_{TR}, tricuspid regurgitant velocity.

Pulmonary hypertension may be associated with a number of conditions (Table 1). A multimodality approach is required to make the correct diagnosis, with particular reliance on imaging techniques and cardiac catheterisation[2-4]. A detailed echocardiographic assessment is required, not just to identify pulmonary hypertension, but also to identify underlying contributing pathology. In particular, it has a crucial role in identifying left-sided cardiac disease and congenital heart disease and an echocardiogram performed for the assessment of pulmonary hypertension should not ignore these aspects. The protocol described in this booklet will not include a description of how to assess these conditions.

In addition to providing essential diagnostic information, transthoracic echocardiography is used to assess severity of right ventricular dysfunction, providing prognostic information and a non-invasive means of following disease progression or response to therapy. As discussed in more detail in Echocardiography Reporting, isolated abnormalities on echocardiography should be interpreted with caution.

Classically, pulmonary hypertension is suspected when the estimated pulmonary artery systolic pressure, calculated from the tricuspid regurgitant velocity, is elevated, however, this may be underestimated due to an insufficient envelope or eccentric jet. Alternatively, it may be low due to a failing right ventricle. Consequently, when pulmonary hypertension is suspected, other surrogate measurements of pulmonary hypertension should be examined by echocardiography (Figure 1). When one or more of these is identified, further assessment of right ventricular function should be considered. **These criteria are guides, not rules, and have been selected by consensus: it is important not to place too much emphasis on a single value nor consider them as precise thresholds for the diagnosis of pulmonary hypertension.** The experienced Echocardiographer should exercise judgment about the necessity for further right heart evaluation in the case of one abnormal result in the context of other normal measurements.

Conversely, it may be necessary to undertake cardiac catheterisation when clinical suspicion is high, even in the context of a normal echocardiogram, for example in patients with a high pre-test probability of pulmonary hypertension with unexplained breathlessness, e.g., scleroderma, and this decision rests with the physician overseeing the patient's care. The final diagnosis of pulmonary hypertension can only be made by cardiac catheterisation as pressure can only be estimated from echocardiography. The diagnostic criteria for pre-capillary pulmonary hypertension (categories 1,3,4 & 5) are:

- Mean pulmonary arterial pressure ≥ 25 mmHg
- Pulmonary capillary wedge pressure ‹ 15 mmHg
- Normal or reduced cardiac output

Conditions other than pulmonary hypertension may affect the right ventricle, including congenital, myocardial and valvular disease. In this protocol, we describe how various echocardiographic views and measurements may be used to differentiate between these conditions, for example differentiating between volume-loading of the right ventricle due to tricuspid insufficiency or left-to-right shunting and pressure-loading due to increased right ventricular afterload.

There are many more parameters which can be measured to assess right ventricular function, including speckle tracking and 3D imaging. We have chosen to include only the parameters used in regular clinical use. We hope this booklet will be of use not only to those undertaking echocardiographic examinations of patients, but also those interpreting the results in a clinical context, including physicians from cardiological and non-cardiological backgrounds.

November 2010

Right Ventricular Anatomy

The complex anatomy of the right ventricle is an important consideration in its assessment. It is the most anteriorly situated cardiac chamber, located immediately behind the sternum. It also marks the inferior border of the cardiac silhouette. In contrast to the near conical shape of the left ventricle, the right ventricle is more triangular in shape when viewed from the front and in cross section the normal cavity appears crescentic. It curves over the left ventricle and this results in the right ventricular outflow tract crossing over the left ventricular outflow tract, in front and above it. Two anatomical components which make the right ventricle difficult to examine in detail, especially when using two-dimensional echocardiography, are the irregular shape of the cavity and the heavy trabeculation making the identification of right ventricular borders difficult.

Right Ventricular Pathophysiology[30-32]

The right ventricle is connected to the pulmonary vascular bed, which, in health, is a low-resistance system, in contrast to the left ventricle and the systemic circulation. It is more compliant than the left ventricle and adapts better to volume-loading than pressure-loading. The left and right ventricles do not function independently of one another and the mechanics of one ventricle will impact on the other. This concept is termed ventricular interdependence and is mediated mainly by the interventricular septum[16].

Septal geometry and motion is largely influenced by the ventricular pressure difference. Under normal circumstances, the considerably higher pressures in the left ventricular cavity render it circular in cross-section and the septum bows in to the right ventricle. Pressure-loading of the right ventricle resulting from increased pulmonary artery pressure, causes the septum to flatten in systole as the right and left ventricular pressures begin to converge and when the right ventricle becomes severely pressure loaded, the septum may even bulge in to the left ventricular cavity. In a volume-loaded right ventricle with diastolic dysfunction and high end-diastolic pressures, the septum will flatten in diastole. These changes will impact on both left ventricular systolic and diastolic function.

In acute pressure-loading, such as pulmonary embolic disease, the right ventricle will dilate and its free wall will become hypokinetic, but chronic progressive pressure-loading, as in pulmonary hypertension, will lead to right ventricular remodeling, notably hypertrophy. The process is not like the physiological hypertrophy of an athlete's heart, but will also result in myocardial

fibrosis, inflammation, myocyte apoptosis and necrosis (forms of cell death) and abnormal contractile function. Right ventricular systolic and diastolic function will therefore deteriorate and it is thought these parameters determine exercise capacity, symptoms and prognosis. The assessment of right ventricular function is therefore a key component of the assessment of a patient with pulmonary hypertension.

Right ventricular dilatation leads to tricuspid annular dilatation, often resulting in significant tricuspid regurgitation. When this is coupled with already-present systolic dysfunction and increased afterload, this will further reduce 'forward' stroke volume in to the pulmonary circulation and resultant cardiac output. The additional volume-loading as a consequence of this will further impair right ventricular diastolic function, increase right ventricular end-diastolic pressure and displacement of the interventricular septum.

The filling pattern of the right ventricle will alter as diastolic function worsens. As relaxation first becomes impaired, early diastolic filling is reduced and there is an increase in filling due to atrial contraction. This results in the reversal of the transtricupsid E:A ratio in association with prolonged isovolumic relaxation time. With progressive diastolic impairment, right atrial pressure increases, leading to increased early diastolic filling, so that the diastolic filling pattern pseudonormalises. With very severe impairment, isovolumic relaxation time may shorten due to high right atrial pressure and the restrictive characteristics of the right ventricle.

Proximal coronary blood flow to the right ventricle occurs in systole and diastole. More distally, flow is predominantly diastolic. Ventricular hypertrophy, increased wall tension in systole and diastole and impaired cardiac output reduce coronary artery driving pressure and increased oxygen demand, which may result in right ventricular ischemia.

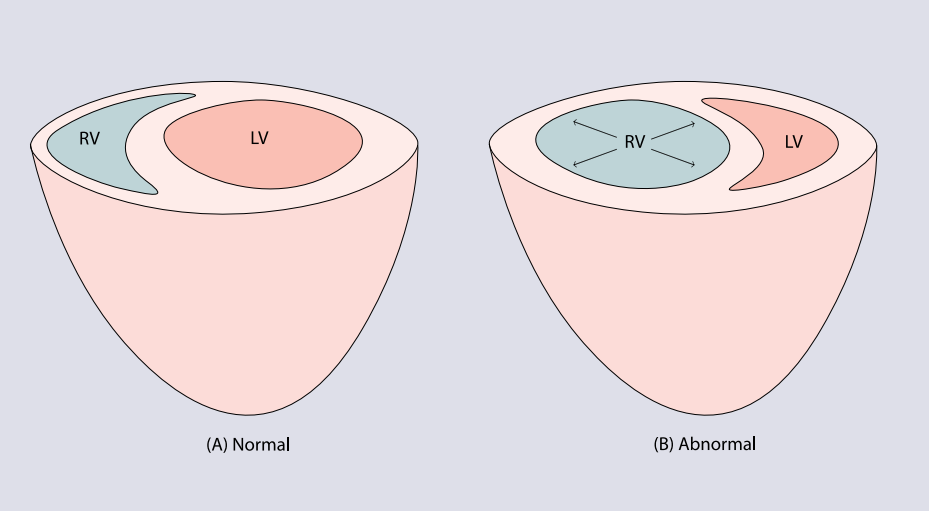

Figure 2. Change from the normal (A) configuration of the right and left ventricles to that seen in pulmonary hypertension (B). Due to the increase in wall stress and intraventricular pressure, the right ventricular walls hypertrophy, its cavity dilates and the interventricular septum bows in to the left ventricle.

Right Ventricular Measurements

	Normal	Indeterminate	Abnormal
RVSP (mmHg)[1]	‹ 37		≥ 37 ≥ 40 (in obese subjects) ≥ 44 (aged over 60)
TR velocity (m/sec)[1]	‹ 2.6		≥ 2.6 ≥ 2.8 (in obese subjects) ≥ 2.9 (aged over 60)
RA volume index (ml/m²)[9]	≤ 34 (men) ≤ 27 (women)		› 34 (men) › 27 (women)
RA pressure (mmHg)[9]	‹ 5	5-10	› 10
RV fractional area change [9, 33, 34]	32 - 60 %		≤ 32 %
RV MPI (Tei index)* [9, 20-22]	‹ 0.28	0.28 - 0.32	› 0.32
TAPSE (mm) [9, 11-13, 28, 29]	≥ 20	16 - 20	‹ 16
S' wave of tricuspid annulus (cm/sec)* [14, 35]	› 12	11.5 - 12	‹ 11.5
RVOT AT (msec)* [8-10]	› 110	105 - 110	‹ 105
IVRT (msec)* [9, 15-17]	‹ 75		≥ 75
LV eccentricity index [9, 24, 25]	1		› 1 at end-diastole indicates volume-loading of the RV › 1 at end-systole indicates pressure-loading of the RV
PVR (Wood units) [26-27]	‹ 1	1 – 3	› 3

*Heart – rate indexed (when rate ‹ 70 or › 100 beats per minute): 75 x value / HR

Table 2. Normal values for the right ventricle and pulmonary circulation: RVSP: right ventricular systolic pressure, TR: tricuspid regurgitation, RA: right atrium, RV: right ventricle, MPI: myocardial performance index, TAPSE: tricuspid annular plane systolic exertion, S' wave : systolic wave, RVOT: right ventricular outflow tract, AT: acceleration time, IVRT: isovolumic relaxation time, LV: left ventricle, PVR: pulmonary vascular resistance.

Pulmonary Hypertension/ Right Heart Imaging Protocol

1. PARASTERNAL WINDOW:
   a. Parasternal long-axis of the left ventricle
   b. Parasternal long-axis of the right ventricular inflow tract
   c. Parasternal long-axis of the right ventricular outflow tract
   d. Parasternal short-axis of the left ventricle – aortic root level
   e. Parasternal short-axis of the left ventricle – mitral valve level
   f. Parasternal short-axis at mid-left ventricular level – papillary muscles
   g. Parasternal short-axis view at the apex – no internal landmarks

2. APICAL WINDOW
   a. Apical "four-chamber" view (include both atrio-ventricular valves)
   b. Apical "five-chamber" view (include the left ventricular outflow)

3. DOPPLER EXAMINATION IN THE FOLLOWING SEQUENCE:
   a. Colour Doppler in all apical projections
   b. Colour Doppler in parasternal projections (long-axis/short-axis)
   c. Pulsed-wave Doppler for transmitral velocities
   d. Pulsed-wave Doppler for left ventricular outflow tract
   e. Pulsed-wave Doppler for the tricuspid inflow
   f. Pulsed-wave Doppler for the right ventricular outflow tract
   g. Continuous-wave Doppler across the left ventricular outflow-aortic valve
   h. Continuous-wave Doppler across the tricuspid valve (for tricuspid regurgitation)
   i. Continuous-wave Doppler across the pulmonary valve (for pulmonary regurgitation)
   j. Tissue Doppler index of the right ventricular free wall
   k. Tricuspid annular plane systolic exertion (M-mode)

4. SUBCOSTAL VIEW
   a. Four-chamber view
   b. Atrial septum
   c. Inferior vena cava

Protocol In-Depth

Parasternal Long Axis View of the Left Ventricle

STRUCTURES SEEN:

- Anterior right ventricular wall
- Moderator band
- Interventricular septum
- Left ventricular posterior wall
- Right ventricular cavity
- Left ventricular cavity
- Left atrium
- Aortic valve (right and non coronary cusps)
- Mitral valve (anterior and posterior leaflets)
- Posterior mitral annulus
- Aortic root & ascending aorta

Measurements	Normal range (men)	Normal range (women)	Pulmonary Hypertension
Left ventricle end-diastolic diameter (cm)[9, 36, 37]	4.2 – 5.9	3.9 – 5.3	↓
Left ventricle end-systolic diameter (cm)[9, 36, 37]	2.1 – 4.0	2 -4	↓
Interventricular septum (cm)[9, 36, 37]	0.8 – 1.1	0.8 – 1.1	–
Posterior wall (cm)[9, 36, 37]	0.8 – 1.1	0.8 – 1.1	–
Aortic root diameter (cm)[9, 36, 37]	3.1 – 3.7	2.7 – 3.3	–
Left atrial linear dimension (cm)[9, 34, 36, 37]	3.0 – 4.0	2.7 – 3.8	–

Table 3. Normal range of measurements.

In normal subjects, the anterior right ventricular wall is usually thin and its mass is less than one sixth of the left ventricle. The diameter of the right ventricle (figure 3a) is less than one third of the left ventricle, in this view.

In pulmonary hypertension (figure 3b), the right ventricle will appear dilated and in the parasternal long axis view, the moderator band is usually seen traversing the right ventricle, close to the interventricular septum. Care should be taken not to include the moderator band in the measurements of the interventricular septal thickness. In significant pulmonary hypertension, the left ventricular cavity may be reduced in size in both systole and diastole, with deviation of the septum towards the left ventricle.

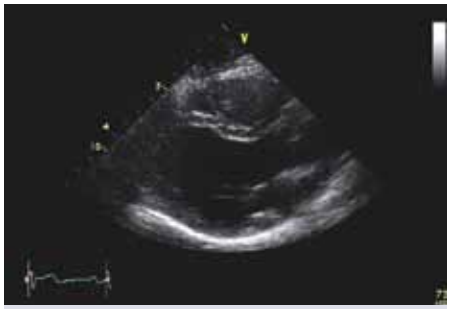

Figure 3a. Normal: parasternal long axis: note that the right ventricle is less than one third of the size of the left ventricle.

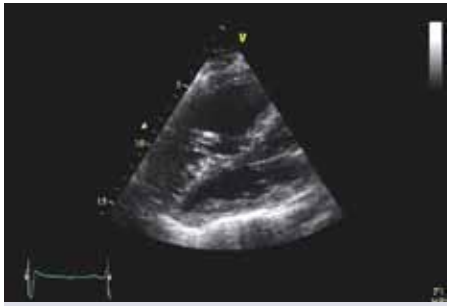

Figure 3b. Pulmonary hypertension: severely dilated right ventricle, with hypertrophy of the moderator band and the right ventricular free wall. The left ventricular cavity is small due to chronic right ventricular pressure overload.

Parasternal Long Axis View of Right Ventricular Inflow Tract

STRUCTURES SEEN:

- Inferior portion of the right atrium
- Right ventricular inflow tract
- Two principal papillary muscles (anterior and posterior)
- A smaller supracristal (or conus) papillary muscle
- Tricuspid annulus
- Anterior and septal tricuspid leaflets

The right ventricular cavity is normally small in size and there is good apposition of the tricuspid leaflets with trivial or mild tricuspid regurgitation (a normal echocardiographic finding in around 25% of the population) (figure 4a).

In pulmonary hypertension (figure 4b), dilatation of the right ventricle and atrium will be visible in this view. This may lead to a functional dilatation of the tricuspid annulus and tricuspid regurgitation. When the tricuspid regurgitant jet is eccentric, optimal alignment for estimation of tricuspid regurgitant velocity may be obtained in this view.

Since tricuspid regurgitation may not always be functional in origin, abnormalities of the leaflets and subvalvular apparatus should also be assessed to exclude primary valvular pathology.

Finally, this view may be used to provide a qualitative estimate of right ventricular systolic function.

Measurements	Normal range	Pulmonary Hypertension
Basal diameter of the right ventricle (cm)[7]	3.7 – 5.4	↑
Tricuspid annulus (cm)[7, 38]	1.3 – 2.8	↑
Tricuspid regurgitant velocity (m/sec)[1]	‹ 2.6	↑

Table 4 : Normal range of measurements – Right ventricular inflow view.

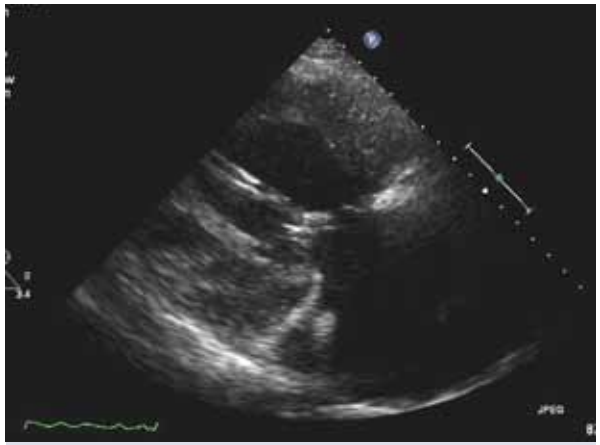

Figure 4a. Parasternal long axis view of the right ventricular inflow tract in a normal subject.

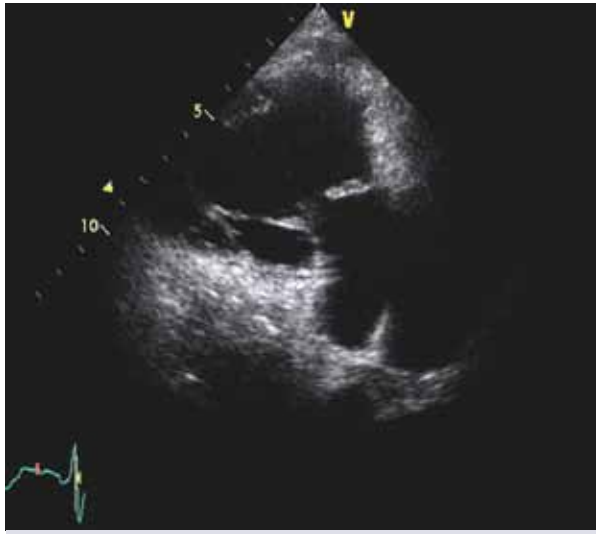

Figure 4b. The same view in a patient with pulmonary hypertension showing marked dilatation of the right heart chambers and tricuspid annular dilatation.

Parasternal Long and Short Axis Views of the Right Ventricular Outflow Tract

STRUCTURES SEEN:

- Right ventricular outflow tract
- Pulmonary valve
- Proximal pulmonary arteries

In normal subjects (figure 5a), the main pulmonary artery and branches are thin-walled structures and at most there is trivial pulmonary regurgitation. In patients with pulmonary hypertension however (figure 5b), the main pulmonary artery becomes dilated in relation to the adjacent aorta, although this is not a sensitive measurement in detecting pulmonary hypertension.

Measurements	Normal range	Pulmonary Hypertension
Right ventricular outflow tract (cm)[7, 9]	1.7 – 2.3	↑
Main pulmonary trunk (cm)[7, 9]	1.5 – 2.1	↑
Right pulmonary artery (cm)[7, 9]	0.7 – 1.7	↑
Left pulmonary artery (cm)[7, 9]	0.6 – 1.4	↑
Right ventricular outflow acceleration time (msec)[8-10]	› 110	↓
Pulmonary regurgitant velocity (beginning of diastole) (m/sec)[5, 6]	‹ 1	↑
Pulmonary regurgitant velocity (end diastole) (m/sec)[5, 6]	‹ 1	↑

Table 5: Normal range of measurements: right ventricular outflow tract.

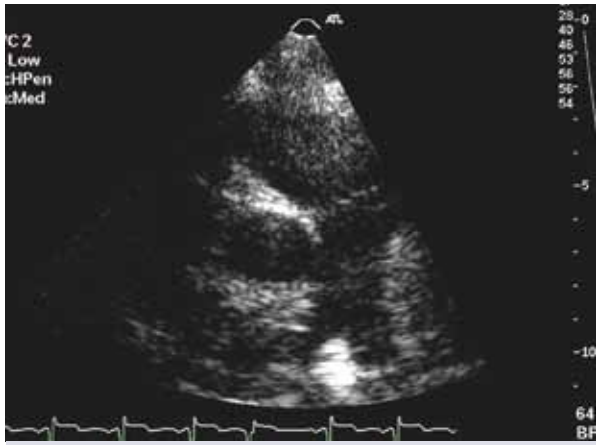

Figure 5a. Parasternal long axis view of the right ventricular outflow tract in a normal patient showing the main pulmonary trunk, branches of the pulmonary artery and the pulmonary valve.

Figure 5b. Pulmonary hypertension: dilated pulmonary artery and branches.

Parasternal Short Axis View of Aorta and Left Atrium

STRUCTURES SEEN:

- Right ventricular outflow tract
- Interatrial septum
- Left atrium
- Right atrium
- Right ventricle
- Tricuspid valve : anterior and septal leaflets
- Aortic valve : left , right and non coronary cusps
- Pulmonary valve
- Main pulmonary artery trunk
- Aorta
- Descending aorta

MEASUREMENTS

The normal values for the measurements which may be made in this view may be found in the sections describing the parasternal long axis of the left ventricle and the parasternal long and short axis views of the right ventricular outflow tract. This view demonstrates the aortic, tricuspid and pulmonary valves simultaneously, making this a useful view for the assessment of structural valvular abnormalities (figure 6a). Furthermore, a zoom view of the interatrial septum with the use colour Doppler may help to identify an atrial septal defect.

As in the other views previously described, pulmonary hypertension will produce right ventricular dilatation and hypertrophy, as well as dilatation of the pulmonary artery (figure 6b).

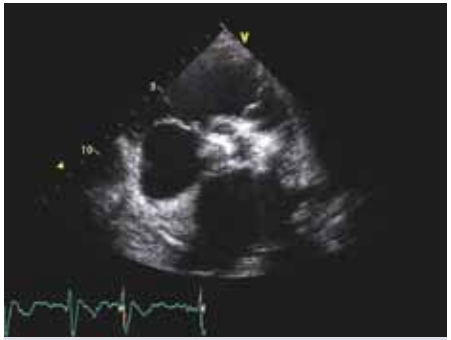

Figure 6a. Parasternal short axis view of the left atrium and aorta in a normal patient.

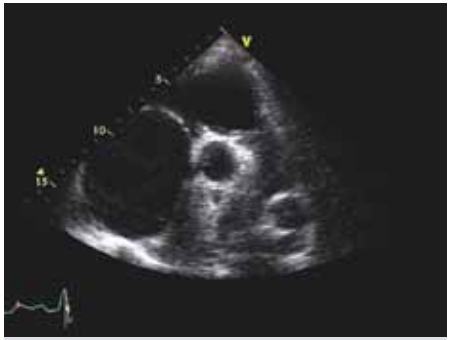

Figure 6b. Pulmonary hypertension: right atrial and ventricular dilatation.

Short Axis View at the Level of Left Ventricular Papillary Muscles

STRUCTURES SEEN:

- Right ventricular anterior wall
- Right ventricular moderator band
- Papillary muscles (anteromedial and posterolateral)
- Tricuspid annulus
- Left ventricle
- Right ventricle

MEASUREMENTS

Eccentricity index of the left ventricle (end-diastolic and end-systolic): the normal value is equal to 1 in both parts of the cardiac cycle[9, 24, 25]. For more details about the changes which occur in pulmonary hypertension, see table 9.

Normally, the left ventricle appears circular in shape, both in systole and diastole. When the right ventricle dilates, the septum shifts towards the left ventricle due to pressure differences across the interventricular septum. This results in the characteristic D-shaped appearance of the left ventricle. Consequently, a right ventricle that is dilated purely due to volume overload will deviate the septum in diastole due to raised end-diastolic pressure and conversely, a pressure-loaded right ventricle will deviate the septum in systole. When pressure-overload is severe the septum may even lie in the left ventricular cavity itself (figure 7b). In most cases of pulmonary hypertension, these two conditions will co-exist.

The degree of distortion of the left ventricle may be quantified by the left ventricular eccentricity index which is described in the next section.

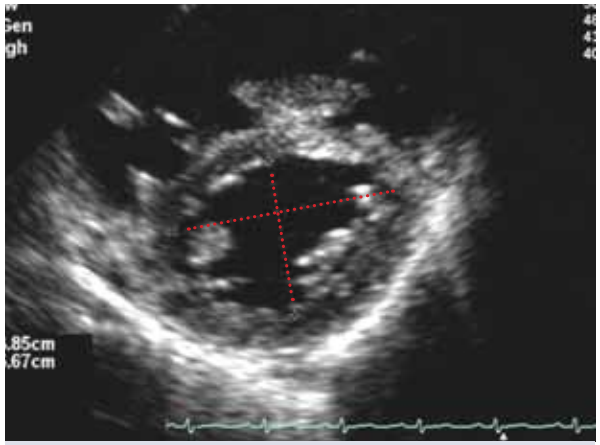

Figure 7a. Parasternal short axis at the level of papillary muscles: measurement of eccentricity index in end-diastole.

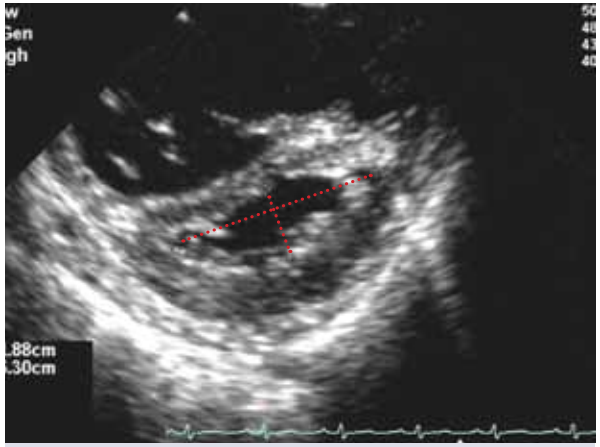

Figure 7b. The same view timed in end-systole.

Apical Four-Chamber View

STRUCTURES SEEN:

- Cardiac crux (the 'centre' of the heart)
- Left ventricular walls : anterolateral, inferior septum and apex
- Right ventricular walls : lateral free wall
- Moderator band
- Tricuspid annulus
- Interventricular and interatrial septum

- Right atrium
- Right ventricle
- Left atrium
- Left ventricle

- Tricuspid valve (anterior and septal leaflets)

- Pulmonary venous drainage: assessment of three of the four pulmonary veins draining into the left atrium is usually possible
- Right upper pulmonary vein : drains into the supero-medial aspect of the left atrium
- The right lower pulmonary vein is not usually seen in this view

Normally, the right ventricle appears triangular in shape and about half the size of the left ventricle in this view and its apex is nearer the base of the heart than that of the left ventricle. In pulmonary hypertension, the cavity dilates and hypertrophies in response to pressure and volume-loading. The apex also hypertrophies and the hypertrophied moderator band is seen traversing it, which should not be misinterpreted as thrombus.

In pulmonary hypertension, the right ventricular wall demonstrates systolic dysfunction and lower myocardial tissue velocities, quantified by tissue Doppler imaging.

Considerable inter-individual variability in the shape and wall motion of the right ventricle, particularly at the apex, is seen in healthy individuals, and relying on one single tomographic view to diagnose abnormal right ventricular function is hazardous.

The tricuspid annulus sits up to 1 cm nearer the apex than the mitral annulus. The tricuspid leaflets demonstrate wide diastolic opening, which become less vigorous as pulmonary hypertension develops.

The tricuspid valve septal leaflet is adjacent to the septum, whereas the leaflet adjacent to the free wall may be either the anterior (most commonly) or posterior leaflet, depending on the exact rotation and angulation of the image plane. Tricuspid leaflets are uniformly echogenic, with normal coaptation in systole. When significant tricuspid regurgitation develops in pulmonary hypertension, careful identification of any structural abnormalities is needed ensure primary tricuspid incompetence is differentiated from secondary incompetence due to the annular dilatation.

Pulmonary Hypertension Echocardiographic Protocol

Measurements	Normal Range	Pulmonary Hypertension
Two-dimensional echocardiography		
Basal diameter of the right ventricle (cm)[7, 9]	2.0 – 2.8	↑
Right ventricular end-diastolic area (cm^2)[7, 9]	11 – 28 cm^2	↑
Right ventricular end-systolic area (cm^2)[7, 9, 39]	7.5 – 16 cm^2	↑
Right atrial area (end-systole) (cm^2)[39]	13.5 ± 2 cm^2	↑
RA volume index (ml/m^2)[9, 18, 19]	≤ 34 (men) ≤ 27 (women)	↑
Tricuspid annulus (cm)[9, 38]	1.3 – 2.8	↑
Right ventricular fractional area change (%)[9, 33, 34]	32 – 60	↓
Doppler echocardiography		
Tricuspid regurgitant velocity (m/sec)[1]	‹ 2.6	↑
Mitral inflow (m/sec) (E and A waves)[40, 41]	0.6 – 1.3	–
Deceleration time – mitral inflow (msec)[40, 41]	110 – 210	–
Left ventricular outflow tract velocity (m/sec)[41]	0.7 – 1.1	–
Aortic flow (m/sec)[41]	1 – 1.7	–
Pulmonary venous inflow[40]		Severe mitral regurgitation: systolic flow reversal
S velocity (cm/sec)	› 50	
D velocity (cm/sec)	› 50	
AR velocity (cm/sec)	› 20	
Tricuspid inflow (m/sec) (E and A waves)[41]	0.3 – 0.7	–
Deceleration time – tricuspid inflow (msec)[41]	144 – 244	↑
RV MPI (Tei index) [9, 20-22 *]	‹ 0.28	↑
TAPSE (mm) [9, 11-13, 28, 29]	≥ 20	↓
TDI right ventricular free wall : IVRT (msec)[9, 15-17]	‹ 75	↑

Table 6. Normal measurements in the apical four-chamber view.

In the four chamber view, the interatrial septum and interventricular septum can be clearly delineated. As for the parasternal short axis of the interatrial septum, “drop-out” artefact is commonly seen in the region of fossa ovalis. This should not be mistaken for an atrial septal defect. The interventricular septum is more muscular and thicker than the interatrial septum, due to higher pressures within the left ventricle compared those within the atria. When the right ventricle becomes pressure-loaded, the septal motion appears dyskinetic, with bowing into the left ventricle.

Finally, the application of tissue Doppler imaging to the septal and lateral left ventricular walls is essential for the exclusion of significant left ventricular diastolic dysfunction. In patients with significant, longstanding pulmonary hypertension, left ventricular diastolic filling may be impaired and there may often be type I or even type II diastolic dysfunction, in very severe cases.

Measurements	Systolic wave (cm/sec)	PH	E’ (cm/sec)	PH	A’ (cm/sec)	PH
RV free (lateral) wall[14, 23, 35]	12 - 20	↓	10.2 – 16.2	↓	6.2 – 10.9	↓
LV septal wall[23]	8.1 – 10.9	↔	9.8 - 16	↔	9 – 13.6	↔
LV lateral wall[23]	9.1 – 12.9	↔	12.5 – 20.5	↔	8.6 – 14.4	↔

Table 7. Normal range of measurements – Tissue Doppler Imaging and normal values

Figure 8a. Normal apical four chamber view.

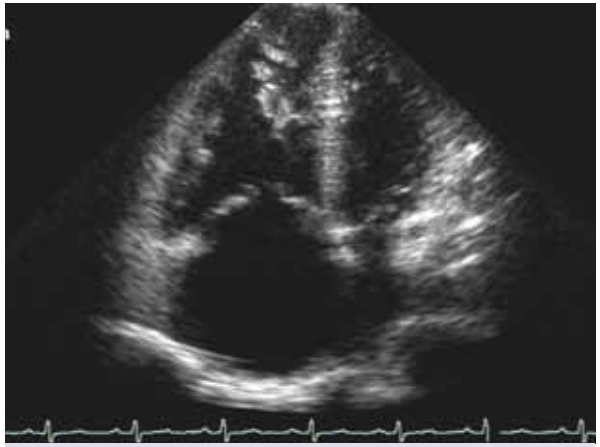

Figure 8b. Apical four chamber view in pulmonary hypertension showing marked right ventricular dilatation and hypertrophy.

Apical Five-Chamber View

STRUCTURES SEEN:

- Left ventricular outflow tract
- Left ventricle : anteroseptal and inferoposterior walls
- Left ventricle
- Left atrium
- Mitral valve: anterior and posterior leaflets
- Proximal ascending aorta
- Pulmonary veins

Subcostal view

STRUCTURES SEEN:

- Right ventricular inferior wall
- Interventricular and interatrial walls
- Left ventricle
- Left atrium
- Right ventricle
- Right atrium
- Tricuspid valve : anterior and septal leaflets
- Mitral valve : anterior and posterior leaflets
- Inferior vena cava : proximal 2-3 cm of the inferior vena cava
- Hepatic veins
- Proximal abdominal aorta

The subcostal view allows estimation of right ventricular dysfunction and thickness of right ventricular walls, especially in patients with difficult parasternal or apical windows, such as those with chronic obstructive pulmonary disease or those who are ventilated. It provides the best view for measurement of right ventricular inferior wall thickness. In addition, the diameter of the inferior vena cava is measured at rest and during inspiration to provide an estimate of right atrial pressure. It is also often the best view to assess for the presence of a sinus venosus atrial septal defect, with or without contrast.

The changes seen in pulmonary hypertension in this view are as described in previous sections.

Pulmonary Hypertension Echocardiographic Protocol

Measurements	Normal range
Right ventricular wall thickness (cm)[7, 9]	0.3 – 0.5
Inferior vena cava (cm)[9]	1.2 – 2.3
Hepatic vein (cm)[9]	0.5 – 1.1
Tricuspid regurgitant velocity (m/sec)[1] *	‹ 2.7
Right atrial volume index (ml/m2)[9, 18, 19] *	≤ 34 (men) ≤ 27 (women)

Table 8. Subcostal view: normal range of measurements. In patients with chronic obstructive disease, ventilated or with difficult parasternal or apical windows

Figure 9. Subcostal view: Right ventricular dilatation and hypertrophy in pulmonary hypertension.

Figure 10. Subcostal view: inferior vena cava measurement and respiratory collapse.

Indexing for Heart Rate

Most indices of function are unaffected by heart rate, yet some require correction when heart rate exceeds 100 or drops below 70. These are right ventricular outflow tract acceleration time, myocardial performance index, S' wave velocity and isovolumic relaxation time. In order to index to heart rate, the measurement should be multiplied by 75/heart rate, eg:

RVOT AT (indexed to HR) = RVOT AT x 75/HR

Indexing for Body Surface Area

When indexing measurements for body surface area (BSA), they should be divided by the BSA (Dupois & Dupois), where:

BSA = 0.007184 X weight (kg)0.425 x height (cm)0.725

For the normal man, BSA is 1.9 m^2 and for the normal woman, BSA is 1.6m^2.

Right Ventricular Pressure *versus* Volume-Loading

Right ventricular volume overload, resulting from an atrial septal defect, tricuspid insufficiency or pulmonary insufficiency, causes an increase in right ventricular end-systolic and end-diastolic volumes with normal right ventricular ejection fraction. Although with time remodelling takes place and left ventricular function becomes affected through ventricular interdependence, left ventricular systolic function is relatively spared.

Right ventricular pressure overload loads the right ventricle predominantly in systole, but also in diastole as both right ventricular end-diastolic and end-systolic volumes increase. An inverse relationship between right ventricular ejection fraction and afterload develops (pulmonary artery pressure or pulmonary vascular resistance). Right ventricular pressure overload therefore distorts both left ventricular systolic and diastolic geometry. The effect on the left ventricle is the reduction of left ventricular ejection fraction, stroke volume, end-diastolic and end-systolic volume, as well as prolongation of the left ventricular isovolumic relaxation time. The different effects of right ventricular volume- versus pressure-loading on the left ventricle are best illustrated by the left ventricular eccentricity index.

Measurements	Volume loading	Pressure loading	Pressure and volume loading
Dilatation	↑↑	↑	↑↑
Hypertrophy	↑	↑↑	↑↑
Contractility	↓ or ↔	↓↓	↓↓
Tricuspid annular dilatation	↑↑	↑	↑↑
Tricuspid regurgitant jet (volume)	↑↑	↑	↑↑
TAPSE	↔ or ↑	↓	↓ or ↔
LV eccentricity index at end-systole	↔	↑	↑
LV eccentricity index at end-diastole	↑	↔	↑

Table 9: Difference in measurements between pressure and volume loading.

Qualitative Assessment of the Right Ventricle

Dilatation

Normally the right ventricle is 1/3 of the size of the left ventricle in the parasternal long axis view. One of the first changes in the right ventricle in response to the increased preload and afterload is dilatation, which progresses with worsening pulmonary hypertension. Dilatation of the right ventricle can be assessed in the parasternal long axis, short axis and the apical four-chamber view. In the apical four chamber view, the right ventricle can be seen to wrap around the apex of the left ventricle as seen in figure 11b.

Figure 11a. Apical four-chamber view. Normal right-sided chambers: the right ventricle is less than one third of the size of the left ventricle .

Figure 11b. Apical four-chamber view. Pulmonary hypertension: dilatation and hypertrophy of the right ventricle.

Hypertrophy

In the face of chronically elevated right ventricular afterload, the right ventricular walls become hypertrophied. One of the first anatomical elements to do so is the moderator band, which in normal subjects it is thin and sometimes difficult to see. From the apical four chamber view, right ventricular hypertrophy is defined by a free wall thickness of more than 5 mm.

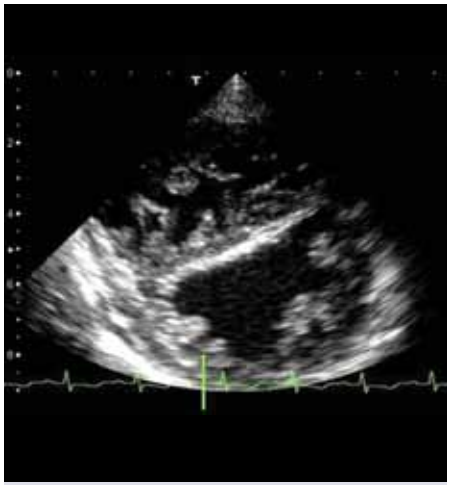

Figure 12a. Dilated and hypertrophied right ventricle seen in left ventricular short axis view.

Figure 12b. The apical four-chamber view.

Contractility

In pulmonary hypertension, right ventricular impairment is global: this is in contrast to other conditions affecting the right ventricle, such as right ventricular infarction or arrhythmogenic right ventricular cardiomyopathy, where there will be regional wall motion abnormalities.

On the basis of these three parameters (dilatation, hypertrophy and contractility), an experienced Echocardiographer will be able to make a good qualitative assessment of right ventricular systolic function, divided in to:

- Mild impairment
- Moderate impairment
- Severe impairment

Pressure Measurements

Right Atrial Pressure

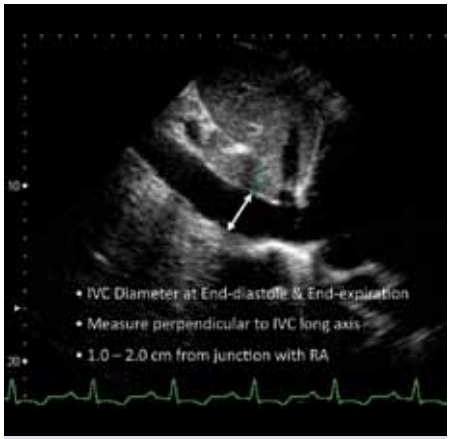

Figure 13a. Subcostal view of the inferior vena cava.

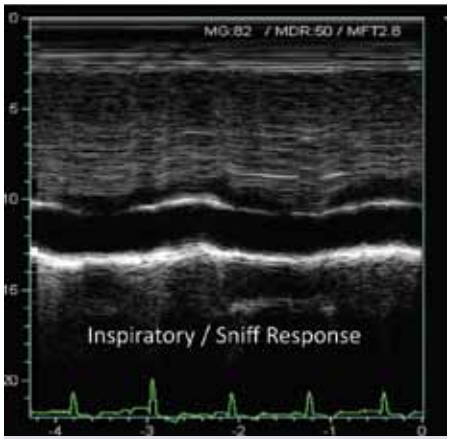

Figure 13b. M-mode during sniff manoeuvre.

From the subcostal view, the inferior vena cava lies perpendicular to the ultrasound beam and M-mode is applied. Measurement of the diameter of the inferior vena cava at end-expiration and during an inspiratory manœuvre provides an estimate of right atrial pressure. If the inferior vena cava diameter is normal (1.5 – 2.5 cm) and the segment adjacent to the right atrium collapses by at least 50% with respiration, then right atrial pressure is normal. Failure to collapse with respiration and/or dilation of the inferior vena cava and hepatic veins is associated with higher right atrial pressures. When there is no response with normal respiration, the patient is asked to "sniff". This generates a sudden decrease in intrathoracic pressure, normally resulting in a decrease in inferior vena cava diameter. Right atrial pressure can be estimated therefore from the size and respiratory motion of the inferior vena cava (Table 10)[9].

Inferior vena cava and diameter	Change with respiration	Estimated right atrial pressure (mmHg)
Small (‹ 1.5 cm)	Collapse	0
Normal (1.5 – 2.5 cm)	Decrease by › 50%	5
Normal	Decrease by ‹ 50%	10
Dilated (› 2.5 cm)	Decrease ‹ 50%	15
Dilated with dilated hepatic veins	No change	20

Table 10. Estimation of right atrial pressure from the inferior vena cava.

Right Ventricular Systolic Pressure (Tricuspid Regurgitant Velocity)

Tricuspid regurgitant velocity is derived from the application of continuous wave (CW) Doppler mapping on the tricuspid regurgitant jet, from the apical four chamber view or from the parasternal right ventricular inflow view, if the regurgitant jet is eccentric. The peak velocity is measured in m/sec.

The velocity reflects the right ventricular to right atrial pressure difference, ΔP, and when pulmonary stenosis is absent, right ventricular systolic pressure (RVSP) is assumed to equal pulmonary artery systolic pressure (PASP), and is calculated through the Bernoulli Equation:

$$\mathbf{PASP = RVSP = 4\,(V_{TR})^2 + RAP}$$

[V_{TR} : tricuspid regurgitant velocity; RAP : right atrial pressure]

The normal expected upper limit of PASP depends on age and body mass index (BMI). In the largest study to date, the estimated upper 95% limit for PASP was 37.2 mmHg in low-risk subjects (V_{TR} 2.6 m/sec), whereas the estimated upper 95% limit for subjects aged 60 and over was 43.6 mmHg (V_{TR} 2.9 m/sec). In those with a BMI › 30 kg/m² the limit was 40 mmHg (V_{TR} 2.8 m/sec). In all these measurements, right atrial pressure was assumed to be 10 mmHg.

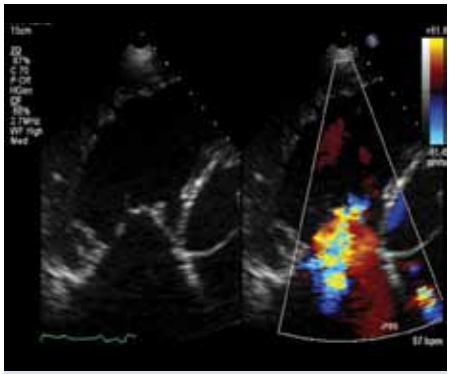

Figure 14a. Continuous wave Doppler across the tricuspid valve.

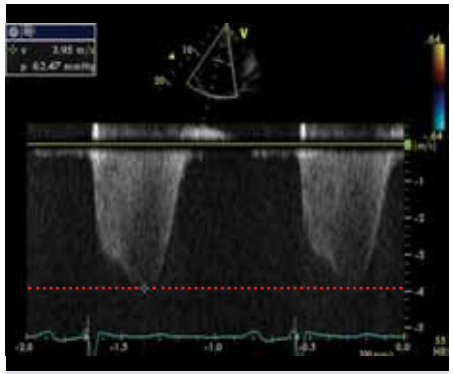

Figure 14b. Measurement of peak tricuspid regurgitant velocity.

A number of studies have highlighted the problem of relying solely on estimates of PASP from echocardiography to diagnose/exclude pulmonary hypertension[42, 43]. In patients with scleroderma being screened for pulmonary hypertension, a cut-off V_{TR} of 2.7 m/sec has a sensitivity of 88% for the detection of pulmonary hypertension[42]. Some of the patients "missed" using this cut-off had mean PAP › 40 mmHg.

Note that in cases of severe free-flow tricuspid regurgitation, the Bernoulli equation is not valid and the tricuspid regurgitant velocity will underestimate the transtricuspid pressure gradient: however, the severity of the tricuspid regurgitation is predictive of survival regardless of the PASP, irrespective of the underlying disease[44]. Severity may be assessed by a number of measurements, including assessment of the structure of the valve, jet area (Table 11) and density and hepatic vein flow[45]. Density is assessed using continuous wave Doppler. Systolic hepatic vein flow reversal usually indicates severe tricuspid regurgitation, whereas blunting of systolic flow indicates moderate regurgitation. None of these measurements should be considered in isolation and it should be re-emphasised that the severity of tricuspid regurgitation is distinct from the velocity.

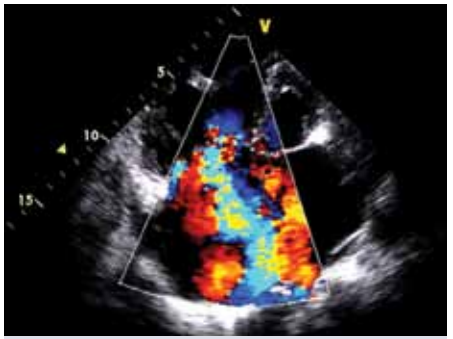

Figure 15. Severe tricuspid regurgitation.

Parameter	Mild	Moderate	Severe
Jet area – central jets (cm²)	‹ 5	5 – 10	› 10
Vena contracta width (cm)	Not defined	‹ 0.7	› 0.7
Proximal isovolumic surface area radius (cm)	≤ 0.5	0.6 – 0.9	≥ 0.9

Table 11. Quantification of tricuspid regurgitation[45].

Pulmonary Artery Mean and Diastolic Pressure

With two-dimensional echocardiography, the pulmonary valve is imaged from the parasternal short axis (at the level of the aortic valve). In some patients with difficult acoustic views, imaging of the pulmonary valve is difficult. The imaging of the cusps in particular, is best done from the parasternal short axis projection because the same view helps the imaging of the pulmonary artery and its division into right and left pulmonary branches.

Another view which might help the imaging of the pulmonary valve is the parasternal projection of the right ventricular outflow tract and the pulmonary valve, with the rotation of the transducer 90 degrees towards the right arm of the patient. This view is difficult in patients with high body mass index, but it is feasible in young people, especially children. Another transthoracic projection is the subcostal view, which, with anterior angulation, can include the whole right ventricular outflow tract and pulmonary valve.

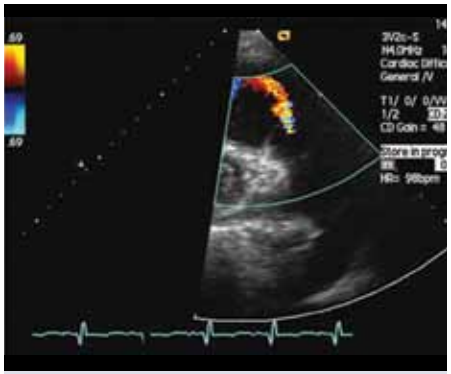

Figure 16a. Pulmonary regurgitation: continuous wave Doppler.

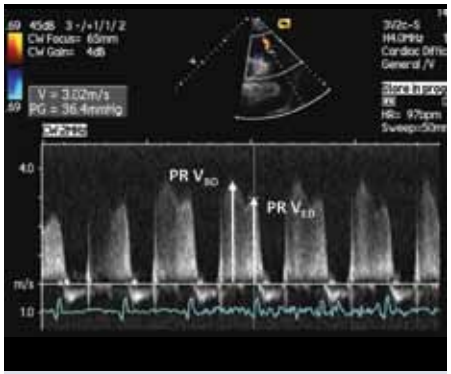

Figure 16b. Measurement of pulmonary regurgitant velocity at beginning of diastole (V_{BD}) and end-diastole (V_{ED}).

The pulmonary valvular motion can be determined with M-mode echocardiography and M-mode can highlight potential pulmonary stenosis, for example in children with Tetralogy of Fallot. Atypical pulmonary valvular motion was one of the first abnormalities to be described in pulmonary hypertension, as an indirect sign of right ventricular failure.

As with the tricuspid regurgitant jet, the Bernoulli Equation can be applied to calculate pulmonary arterial end-diastolic pressure (PEDP)[5, 6] :

$$\textbf{PEDP} = 4(V_{ED})^2 + \textbf{RAP}$$

[V_{ED}, end-diastolic pulmonary regurgitant velocity]

Mean pulmonary artery pressure, may also be derived from the pulmonary regurgitant velocity:

$$\textbf{Mean PAP} = 4(\textbf{PR } V_{BD})^2$$

[V_{BD}, beginning of diastole pulmonary regurgitant velocity]

Measurement of PEDP and mPAP is not routinely used in the diagnosis or follow-up pulmonary hypertension, but may be useful in its identification when tricuspid regurgitant velocity cannot be used or relied upon.

Right Ventricular Outflow Tract Acceleration Time*

Right ventricular outflow tract acceleration time (RVOT AT) is the time in milliseconds from the beginning of the pulmonary ejection until the maximum of the systolic velocity. It is measured by pulsed-wave Doppler with the sample volume positioned at the centre of the pulmonary artery, ideally at the annulus, in the parasternal short axis view of the right ventricular outflow tract.

In normal people, the acceleration time exceeds 140 ms and it shortens in pulmonary hypertension. There is an inverse relationship between AT and mean PAP and several equations have been described:[8-10]

Mean PAP = 79 – (0.45 x AT)

Mean PAP = 90 – (0.62 x AT)

$\log_{10}$mean PAP = 0.0068.AT + 2.1

but these are not commonly used to derive pressure in clinical practice as they have been superseded by tricuspid regurgitant velocity. Nonetheless, acceleration time may be a useful measure when the tricuspid velocity cannot be measured, particularly at diagnosis. A value below 105 ms is suggestive of pulmonary hypertension.

*RVOT AT should be indexed for heart rate.

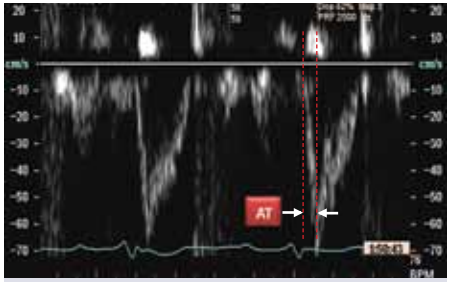

Figure 17. Acceleration time measured across the pulmonary outflow tract in the parasternal short axis view.

Cavity Measurements (2D)

Measurement of RA volume index

The measurement of right atrial (RA) volume index is usually performed from the apical four-chamber view or from the subcostal view. Atrial volume is measured at end-systole, where the maximum atrial volume can be obtained.

The single plane area-length method is used and RA volume is measured using the area and the long axis length of the atrium[9, 18, 19]:

RA volume index = (0.85 A2/ L) / BSA

[A, area of atrium in any view (cm^2); L, long axis length of atrium (cm); BSA, body surface area]

An alternative method for measuring right atrial volume index from the apical four-chamber is the method of discs or Simpson's rule. In this plane, the disc diameters at various levels of the atria are used to determine the cross-sectional area.

The normal right atrial volume when indexed for body surface area is 34 ml/m^2 for men and 27 ml/m^2 for women.

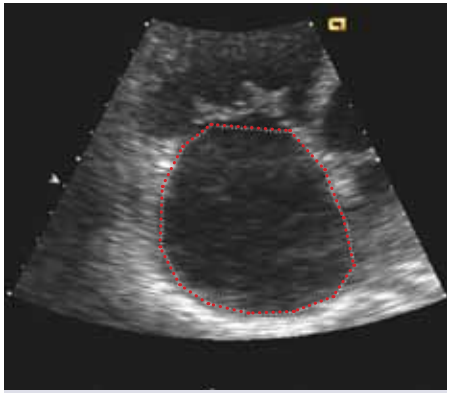

Figure 18a. Measurement of right atrial area for calculation of right atrial volume.

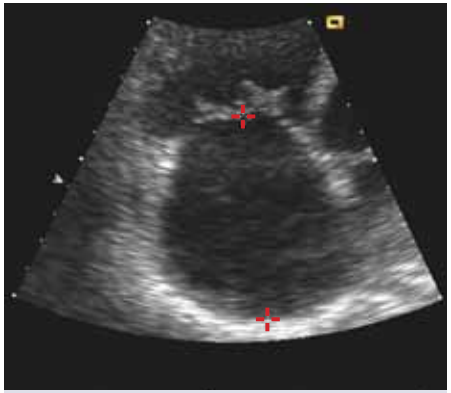

Figure 18b. Measurement of right atrial long axis for calculation of right atrial volume.

Right Ventricular Fractional Area Change

Right ventricular fractional area change (FAC) is calculated as follows:

$$\text{RV FAC (\%)} = (A_{ED} - A_{ES}) \,/\, A_{ED}$$

where A_{ED} is end-diastolic area and A_{ES} is end-systolic area, measured from the apical four-chamber view[9, 33, 34]. It is a simple method for assessment of right ventricular systolic function which has been shown to correlate with ejection fraction measured using cardiac MRI[34] and prognosis in pulmonary hypertension. It also correlates with response to treatment[46].

	Normal	Abnormal
RV diastolic area (cm²)	11 – 28	› 28
RV systolic area (cm²)	7.5 – 16	› 16
RV fractional area change (%)	32 – 60	‹ 32

Table 12. Two-dimensional measurements of right ventricular area

Left Ventricular Eccentricity index

Eccentricity index is measured by the parasternal short-axis at the level of left ventricular papillary muscles. It is measured as the ratio of the minor axis of the left ventricle parallel to the septum (D2), divided by the minor axis perpendicular to the septum (D1) (Figure 19).

The index is measured in end-diastole and end-systole. In a purely pressure-loaded right ventricle, there is flattening of the interventricular septum in end-systole, which results in increased end-systolic left ventricular eccentricity index. In pure volume-loading, the eccentricity index will be increased in end-diastole[9, 24, 25].

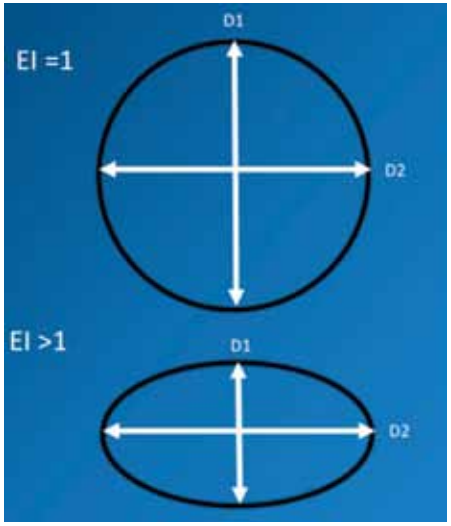

Pulmonary Hypertension Echocardiographic Protocol

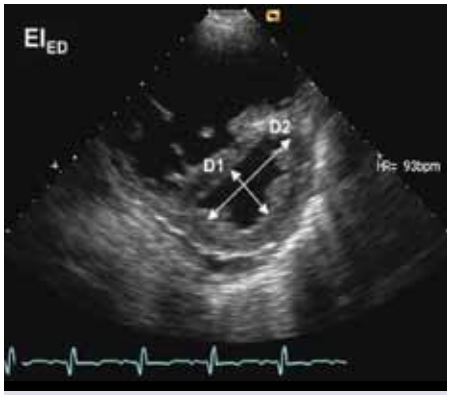

Figure 19a. Measurement of left ventricular eccentricity index in end-diastole (EI_{ED}).

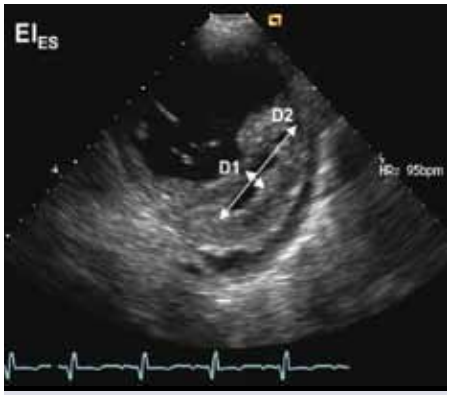

Figure 19b. Measurement of left ventricular eccentricity index in end-systole (EI_{ES}).

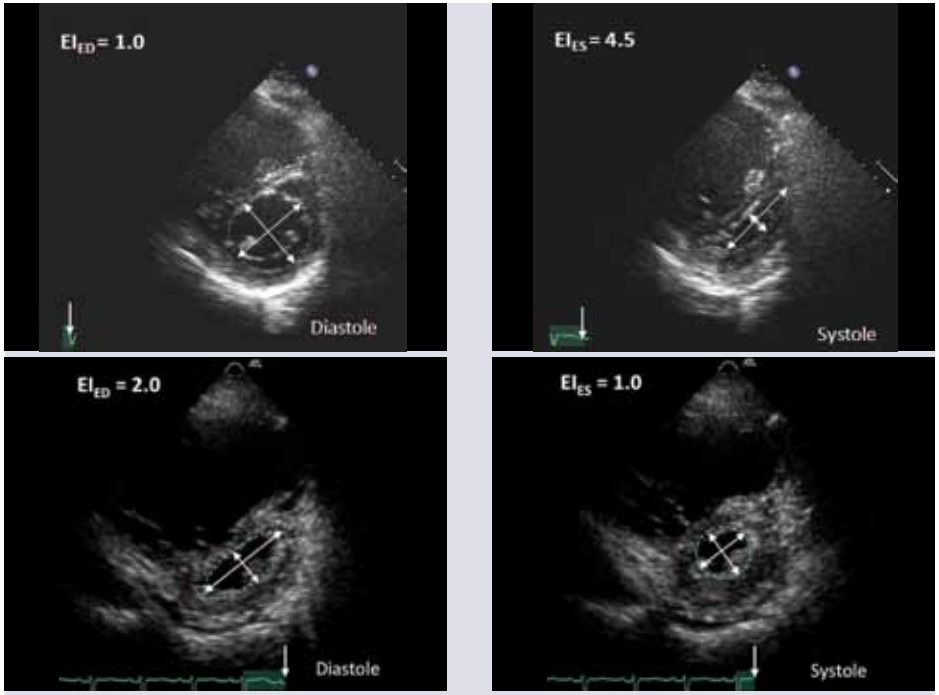

Figure 20. Examples of the effects of pressure-loading (top two panels) and volume-loading (bottom two panels) of the right ventricle on the eccentricity index of the left ventricle.

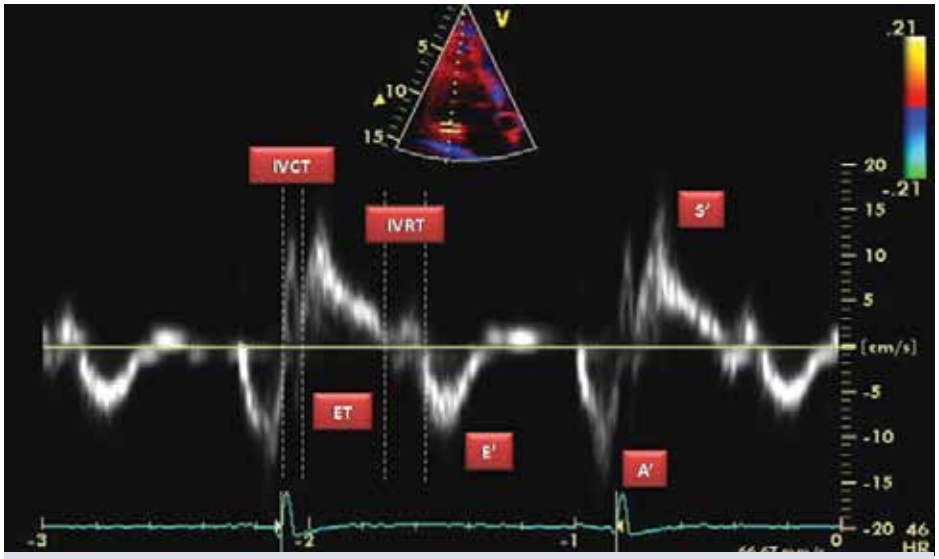

Figure 21. Measurements made during tissue Doppler imaging of the free right ventricular wall at the level of the tricuspid annulus from the apical four-chamber view. A', late (atrial systole) myocardial diastolic wave; E', early myocardial diastolic wave; ET, ejection time; IVCT, isovolumic contraction time; IVRT, isovolumic relaxation time, S', systolic myocardial wave. Measurements are made in held end-expiration.

Tissue Doppler Imaging (TDI)

PULSED MODE TDI:

Peak velocities and the acceleration and deceleration of structures can be measured. A pulsed-wave Doppler sampling gate of 2-4 mm and a sweep of 100-150 mm/sec are used.

CONVENTIONAL COLOUR DOPPLER MAPPING:

The advantages of this technique include the capacity for rapid assessment of movement, the ability to measure velocity of structures in numerous myocardial segments at once and good spatial resolution with accurate discrimination between subepicardial and subendocardial myocardial layers.

Measurements are made from the apical four-chamber view, with the patient holding their breath in end-expiration.

Right Ventricular Diastolic Dysfunction

DIASTOLIC DYSFUNCTION COMPRISES:

- poor relaxation
- decreased compliance
  (change in unit volume per unit pressure)

TDI of the tricuspid apparatus is less pre-load-dependent than conventional Doppler. The E' and A' waves represent myocardial velocity corresponding to the E and A waves on tricuspid inflow measured by conventional colour Doppler, that is filling in early diastole and during atrial systole respectively. The E wave is dependent on right ventricular filling and right atrial pressure and the E wave velocity will be higher with high right atrial pressure (ie, pre-load), and lower with impaired right ventricular relaxation. In some circumstances these two physiological parameters may therefore balance each other out. TDI has been proposed as a way of determining whether a 'normal' tricuspid inflow is actually 'pseudonormal'. With a pseudonormal pattern (E/A › 1), restriction and impaired relaxation are balanced, and the E/A ratio is pseudonormal due to high right atrial pressure. E' wave velocity, representing early diastolic movement of the tricuspid annulus, will still be abnormal as it is relatively pre-load-independent.

Diastolic function of the right ventricle can be assessed with many parameters, and those useful in pulmonary hypertension include:

Isovolumic relaxation time (IVRT) When prolonged, it indicates poor myocardial relaxation. A normal IVRT is 75±12 ms. With abnormal relaxation, the value is usually in excess of 110ms. However, when restriction is present with high right atrial pressures, IVRT will fall below normal to durations less than 60 ms. IVRT is discussed further below.[9, 15-17]

Transtricuspid inflow (E wave deceleration) Deceleration of inflow of the E wave is measured by deceleration time (DT), which shortens with decreasing right ventricular compliance. DT is complex, as higher right atrial pressures also shorten it. A normal DT is 198 ± 23 ms; values over 240 ms indicate impaired relaxation, and under 160 ms suggest restriction.[41]

Measures of Function

Myocardial Performance Index of the Right Ventricle (RV MPI)*

Myocardial Performance Index, also known as Tei Index[21], combines a combination of systolic and diastolic measurements. The normal range for RV MPI is 0.28-0.32[9, 20-22]. It is relatively unaffected by heart rate, loading conditions or the presence and the severity of tricuspid regurgitation. In patients with idiopathic pulmonary arterial hypertension, the index correlates with symptoms and values above 0.88 predict poor survival.

The advantages of its use are good reproducibility, quick calculation, no need for use of geometric models and appliance even in the presence of a difficult acoustic window.

There are two different approaches for the measurement of MPI.

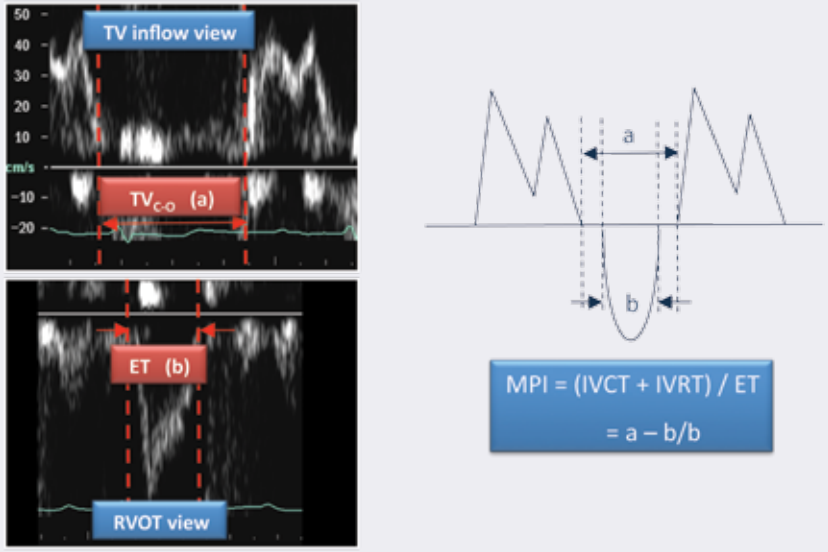

Figure 22. Tricuspid inflow from valve opening to closure (TV_{c-o}) is the sum of isovolumic contraction time (IVCT), ejection time (ET) and isovolumic relaxation time (IVRT). The ejection time – as measured from the short axis RVOT view - is subtracted from TVc-o and the result is divided by ET to give MPI.

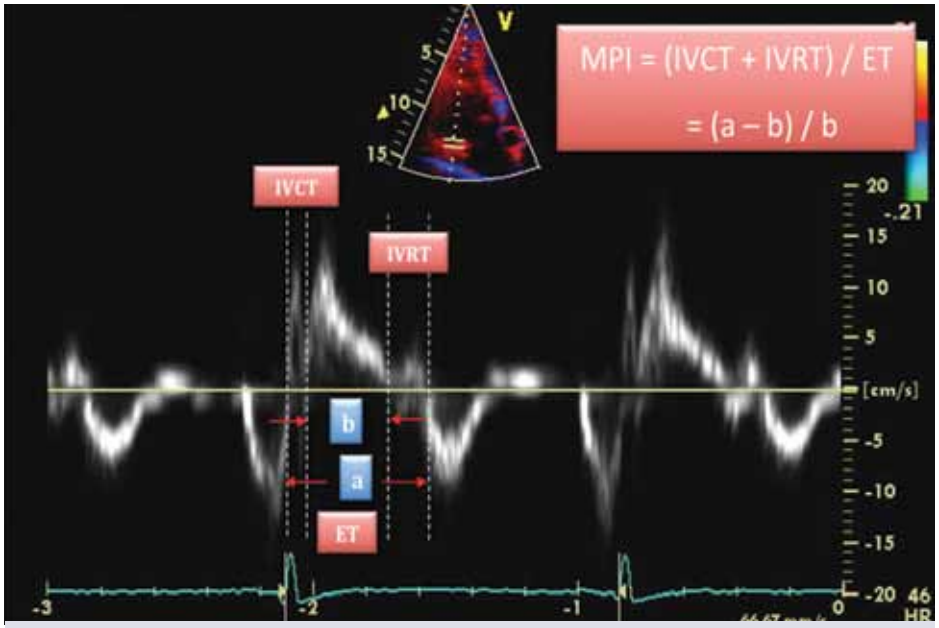

Figure 23. Measurement of MPI using tissue Doppler imaging. See Figure 22.

Colour Doppler (Two views: apical tricuspid inflow and parasternal right ventricular inflow)

Two different views are needed for the determination of MPI - the apical four-chamber view for the tricuspid inflow pattern and the parasternal short axis right ventricular outflow tract view for the determination of ejection time (Figure 22).

Tissue Doppler Imaging (One view: Pulsed-wave Doppler of the right ventricular free wall)

TDI can also be used to derive the same parameters as colour Doppler, but only one view is required (Figure 23).

*MPI should be indexed for heart rate.

S' wave velocity*

The average of three TDI signals from different cardiac cycles is employed for data analysis (Figure 21). The patient has to be in sinus rhythm and the velocities are indexed to the heart rate. The S' wave velocity is normally greater than 12 cm/sec, and we consider a cut-off value of 11.5 cm/sec, below which right ventricular myocardial function may be impaired.[35]

*S' wave velocity should be indexed for heart rate.

Isovolumic Relaxation Time (IVRT)*

Isovolumic relaxation time of the right ventricle is defined as the time from pulmonary valve closure to tricuspid valve opening and can be measured by conventional Doppler echocardiography (pulsed-wave Doppler from tricuspid inflow) or with tissue Doppler imaging on the right ventricular free wall, provided that the patient does not have an irregular heart rate. In Figure 23, it is shown as the time between the end of the S' wave and beginning of the E' wave.

Prolongation indicates poor myocardial relaxation. The normal isovolumic relaxation time is approximately 75±12 ms, and perhaps about 10ms longer in those aged over forty. With abnormal relaxation, the value is usually in excess of 110ms, which is highly suggestive of pulmonary hypertension, which may be useful in the absence of tricuspid regurgitation. It does not provide prognostic value.

With restrictive filling and/or high filling pressures, the interval may fall to below 60ms.

*IVRT should be indexed for heart rate.

Tricuspid Annular Plane Systolic Excursion (TAPSE)

TAPSE is the reflection of the movement the base to apex shortening of the right ventricle in systole (longitudinal function). During ventricular systole, long axis shortening is created by motion of both atrioventricular valve annulae toward the cardiac apex. Because the septal attachment of the tricuspid annulus is relatively fixed, the majority of tricuspid annular motion occurs in its lateral aspect.

The measurement of TAPSE is derived from the apical four chamber view. Special care has to be taken for the whole right ventricle to be included in the view with no dropout in the endocardial outline along the interventricular septum and RV free wall. The width of sector should be limited onto the right ventricular free wall, and the M-mode cursor should be positioned on the lateral portion of the tricuspid annulus, measuring in control sweep mode.

Maximal TAPSE is defined by the total excursion of the tricuspid annulus from its highest position after atrial ascent to the peak descent during ventricular systole. Earlier studies using 2D echocardiography showed that in the normal right ventricle this value exceeds 16 mm[12]. Using M-mode the normal range is higher (24.9 ± 3.5 mm[28]; 25.4 ± 4.9 mm[29]) and a value of 20.1 mm has been shown to be a useful cut-off in identifying pulmonary hypertension[29].

In a volume-loaded ventricle with preserved function, such as in the presence of an atrial septal defect, TAPSE may be very high, over 30mm. In a volume- and pressure-loaded right ventricle, such as a dilated, hypertrophied right ventricle with significant functional tricuspid regurgitation, TAPSE may become pseudonormalised (Table 9: Difference in measurements between pressure and volume loading).

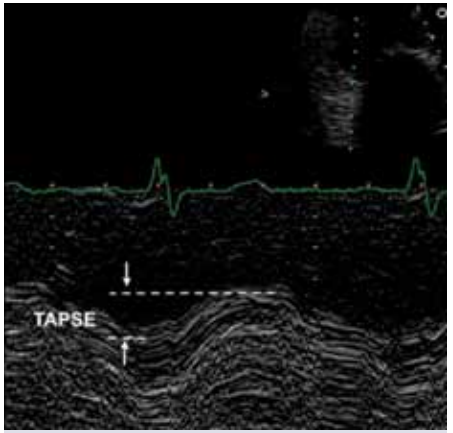

Figure 24. Measurement of TAPSE.

Stroke volume, Cardiac Output and Pulmonary Vascular Resistance

Echocardiography uses the combination of two-dimensional and pulsed-wave Doppler imaging to measure cardiac output. Stroke volume (SV) can be derived from the product of the velocity-time integral (VTI) of the Doppler profile and the cross-sectional area (CSA) of the left ventricular outflow tract (LVOT). Cardiac output (CO) is the product of SV and heart rate (HR).

$$SV = VTI_{(LVOT)} \times CSA_{(LVOT)}$$

$$CO = SV \times HR$$

Similarly, right ventricular SV and CO can be measured from the proximal right ventricular outflow tract (RVOT), just within the pulmonary valve from the parasternal short-axis view. Care should be taken to ensure that Doppler cursor is in line with the axis of the right ventricular outflow tract, otherwise a significant error will appear in the measurements. In order to calculate pulmonary vascular resistance (PVR), continuous-wave Doppler is used to determine the peak tricuspid regurgitant velocity (V_{TR}) as described above: the highest velocity is used. In patients with atrial fibrillation, the average of five measurements should be taken.

$$PVR\ (Wood\ units) = 10.(V_{TR}/VTI_{RVOT}) + 0.16$$

This measurement has been shown to correlate well with PVR measured at cardiac catheterisation over a range of right and left atrial pressures.

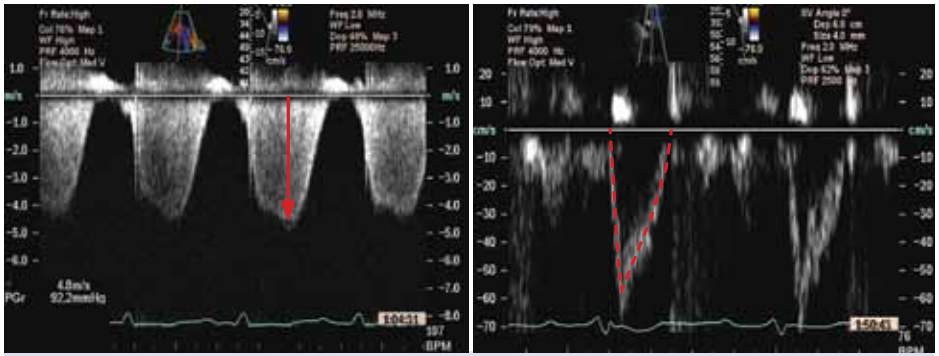

Figure 25. Measurement of PVR from V_{TR} (left) and RVOT VTI (right).

A value of V_{TR}/VTI_{RVOT} less than 0.2 has a 94% sensitivity for a PVR of less than 2 Wood Units at catheterisation[26]. As the definition of pulmonary arterial hypertension (PAH) includes a PVR greater than 3 Wood Units, a V_{TR}/VTI_{RVOT} less than 0.2 will exclude most cases of PAH.

While measures of SV, CO and PVR are readily measurable at echocardiography and correlate with right and left heart function and the underlying pulmonary vascular resistance, these measurements are not considered core to the protocol and are thus not mandatory measurements. The value of serial measurements in the follow-up of pulmonary hypertension has not been validated.

Haemodynamics & Vasoreactivity

When investigating potential cases of idiopathic PAH at cardiac catheterisation, a vasodilator (inhaled nitric oxide, intravenous prostacyclin or adenosine) is given to identify a subgroup which may respond to long-term treatment with calcium channel blockers. A positive vasodilator response is defined by a drop in mean pulmonary arterial pressure by more than 10 mmHg to less than 40 mmHg, with a stable or increasing cardiac output[47]. As yet, echocardiography has not been validated to identify this subgroup and therefore should not be used outside the research setting.

Pulmonary Hypertension Echocardiographic Protocol

Assessing Prognosis and Clinical Course in Pulmonary Hypertension

The primary abnormality in pulmonary hypertension is increased afterload on the right ventricle due to elevated pulmonary vascular resistance caused by remodelling of the resistance pulmonary arteries. It is possible that the right ventricle itself is predisposed to abnormal remodelling due to the same genetic abnormalities underlying vascular remodelling, but this is highly speculative. Nonetheless, it is clear from many studies that it is cardiac function which determines prognosis and exercise capacity. In particular, it is worth noting that pulmonary arterial pressure by itself does not correlate at all well with exercise capacity or prognosis. This is made abundantly obvious from the fact that pulmonary arterial pressure will fall with advancing right ventricular failure.

As right ventricular failure progresses, cardiac output falls and right atrial pressure rises. Values from cardiac catheterisation associated with poor prognosis are[48]:

- Cardiac index ‹ 2.1 l/min/m^2
- Right atrial pressure › 10 mmHg
- Mixed venous oxygen saturation ‹ 63 % (low values indicate increased oxygen extraction due to lower cardiac output)

In line with these measurements, echocardiographic follow-up studies have shown **increased right atrial** size to be associated with poor prognosis[49]. Persistently high right atrial pressure may lead to the development of a **pericardial effusion**, which is a powerful predictor of mortality[49].

Other echocardiographic features that have been shown to correlate with survival include markers of myocardial function such as **myocardial performance index (MPI), right ventricular fractional area change** and **tricuspid annular plane systolic excursion (TAPSE)**[50]. A cut-off value of greater than 0.88 for MPI and less than 15 mm for TAPSE have been particularly associated with poor prognosis. Increases in **left ventricular eccentricity index at end-diastole** have also been shown in several studies[49, 50] to be associated with worse outcomes, indicating the adverse impact of left ventricular compression. Patients with values above 1.7 have a significantly higher risk of dying[51].

While it may be important to use cut-off values from echocardiography to risk-stratify patients, there are many other powerful clinical indicators of severity, such as functional class, haemodynamics and exercise capacity. Nonetheless, there are problems with using these measures in following the clinical course of patients or response to therapy. Haemodynamics can only be obtained by invasive means; functional class is a crude assessment for only small to moderate change; and exercise capacity can be influenced by many other factors.

Echocardiography therefore provides invaluable additional information when assessing prognosis and the clinical course of disease. No clinical or physiological measure should be considered in isolation and often several modalities of assessment are required to reach a conclusion about the status of a patient, so that a physician or team may be able to determine a course of action. Equally, patients may report stability or improvement in symptoms, but progressive or persistent concerning features on echocardiography may lead suggest the need for continued escalation of treatment or more detailed assessment. How all of these parameters are integrated in to a treatment strategy is beyond the scope of this protocol.

Assessment of Pulmonary Hypertension in Children

This very short overview takes advantage of its position at the end of this booklet with the pathophysiology and basics of echocardiography well set out before, and thus can afford to focus only on the differences in children. The suggestions reflect most of the practice of the "UK Service for Pulmonary Hypertension in Children", a network set up in 2001, which spans the entire country, with all types of pulmonary hypertension, from infancy to young adulthood. Within this young subject, the practice is still evolving.

Pulmonary Hypertension in Children

Pulmonary Hypertension in children comes in different forms and severities. Some subtypes are very aggressive (idiopathic; some of those associated with congenital heart disease), while other forms may tend to stabilize and can rarely improve after an initially stormy period, profiting from treatment and ongoing cardiac and pulmonary growth. Within Congenital Heart Disease, there is a wide range of defects resulting in complex physiology which one needs to be familiar with in order to correctly judge disease severity and effects of therapy; an overview is given in Table 13.

	Subgroups		
Type of CHD – PH	A	B	C
Significant shunting lesions	For corrective surgery, PVR is low and presents no problem	For corrective surgery, PVR elevated, risk increased but accepted	For corrective surgery, PVR elevated, risk too high, not operable
iPAH-like physiology	Small unoperated lesion (eg., PFO, ASD, VSD, PAD) not haemodynamically related to PAH	Small residual after corrective surgery of a shunting lesion, not haemodynamically related to PAH	
PAH due to past or present PVH	Persisting PH despite corrective surgery of pulmonary venous stenosis or aortic/ mitral valvar disease or coarctation, with **normal** wedge pressure and left ventricular function	PAH due to left ventricular dysfunction with **abnormal** wedge pressure and increased PVR	
Eisenmenger physiology	Classical Eisenmenger physiology: no sub-pulmonary outflow obstruction; predominantly right-to-left shunting at atrial, ventricular or arterial level, no intraventricular mixing	Functionally univenricular physiology: no sub-pulmonary outflow obstruction; systemic desaturation is due to intraventricular mixing	Transposition physiology with cyanosis due to intra cardiac streaming (Sat% PA > Sat% Ao)
Fontan-like physiology	After Fontan-operation with the right atrium being **incorporated**	Fontan with a lateral or extracardiac conduit, right atrium excluded, no fenestration	Anatomy as above under b), with **fenestration**
Unilateral PAH	Due to a **surgical shunt** (BT-Shunt) previously created to increase pulmonary blood flow which has led to significant PAH on that side	Due to **congenital origin** of one pulmonary artery or of major collateral vessels (MAPCA) from the aorta, causing PAH	
Hypoplastic PA System	After corrective surgery of **tetralogy of Fallot** without major anatomical obstructions of the pulmonary vascular system, and PAH	After corrective surgery of **pulmonary atresia** without major anatomical obstructions of the pulmonary vascular system, and PAH	

Table 13. **New proposed classification of pulmonary arterial hypertension in the setting of congenitally malformed hearts as based on circulatory pathophysiology**

Abbreviations: ASD, interatrial communication; (i)PAH, (idiopathic) pulmonary arterial hypertension; PVR, pulmonary vascular resistance; PA system, pulmonary vascular system; Ao, aorta; PAD, persistently patent arterial duct; POF, patent oval foramen; PVH, pulmonary venous hypertension; VSD, Ventricular septal defect, PFO, patent foramen ovale; Sat%, oxygen saturation; MAPCA, Major Aortopulmonary Collateral Arteries.

Practicalities when performing and recording the Echocardiogram

Children may be impatient, and time may be of the essence, thus an effective technique of a swift echocardiographic examination is important, within which high quality and reproducible images can be recorded to allow for valid comparisons of different recordings over time.

The correct choice of the probe delivering the best images in that particular patient matters, and if in doubt, one should try lower or higher MHz probes. Standard views (subxyphoidal, long axis, 4-chamber view, short axis, supraclavicular) should be used first, with correct anatomical orientation and placement of the structures (heart, apex-down, and left-right orientation analogous to the chest radiograph). Going in an S-shaped fashion across the individual positions for the probe on the abdomen and chest will make the examination systematic and reliable. The same is true for going from 2-D to Doppler to M-Mode. Using an upright, anatomically-orientated image in the 4-chamber view may be helpful to understand complex congenital heart disease and is the preferred option in those children.

Saved images should be labeled if not standard; saved loops should contain at least three cardiac cycles to allow eye-balling of cardiac function and to avoid irritatingly flickering recordings of fractions of a cycle. The technique of picking three well recorded cardiac cycles from a frozen loop for recording facilitates echocardiography in the impatient child.

Interpretation of the Echocardiogram

It is characteristic for children to have enormous compensatory reserve mechanisms. Thus, while adults will notice even small changes in their exercise tolerance, children may compensate for pronounced changes in intracardiac architecture or unequivocal reduction of cardiac output until severe echocardiographic features of pulmonary hypertension develop. As in the adult pulmonary hypertension assessment, the grading of the severity is best based not on a single parameter (although a single parameter can reflect the situation) but on a number of parameters which are complimentary and give a reliable and robust picture (Figure 26). Indices of LV function in severe pulmonary hypertension may be meaningless. Parameters such as TAPSE or MAPSE need to be interpreted in relation to either heart size itself, or to body size. Normal values for TAPSE in children are given in Figure 27 overleaf.

PH Stage I (mild)

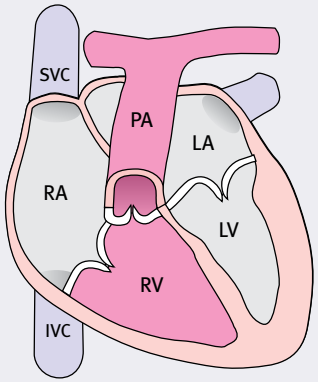

High mean pulmonary arterial pressure
Trace tricuspid regurgitation
Normal right ventricular function

PH Stage II (moderate)

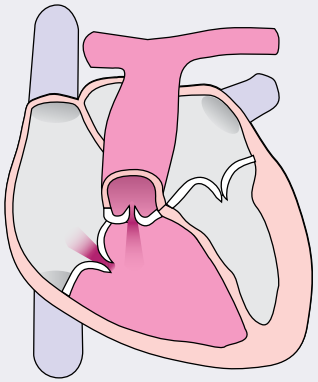

Pulmonary artery mildly dilated
Tricuspid regurgitation present
Mild right ventricular hypertrophy
Mild right ventricular dilation
Good right ventricular function
Enlarged right atrium

PH Stage III (severe, compensated)

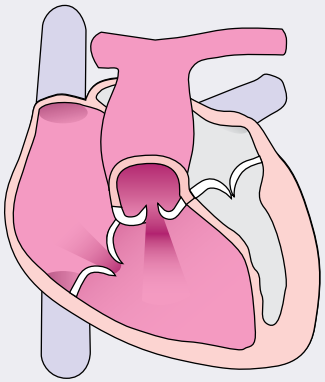

Severely dilated pulmonary artery
Right ventricle hypertrophied and dilated with poor function
“D-shaped” left ventricle
Dilated right atrium and small left atrium

PH Stage IV (decompensated)

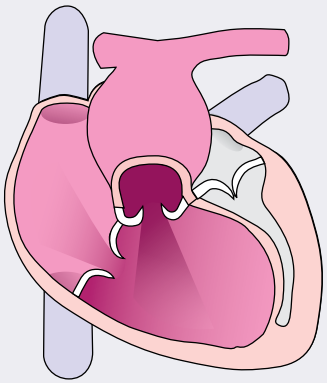

“No” right ventricular function
Severe tricuspid and pulmonary regurgitation
Dilated inferior vena cava
Low velocity time integral (aortic and pulmonary) - poor cardiac output
New York Heart Association Functional Class III-IV

Figure 26.

Pulmonary Hypertension Echocardiographic Protocol

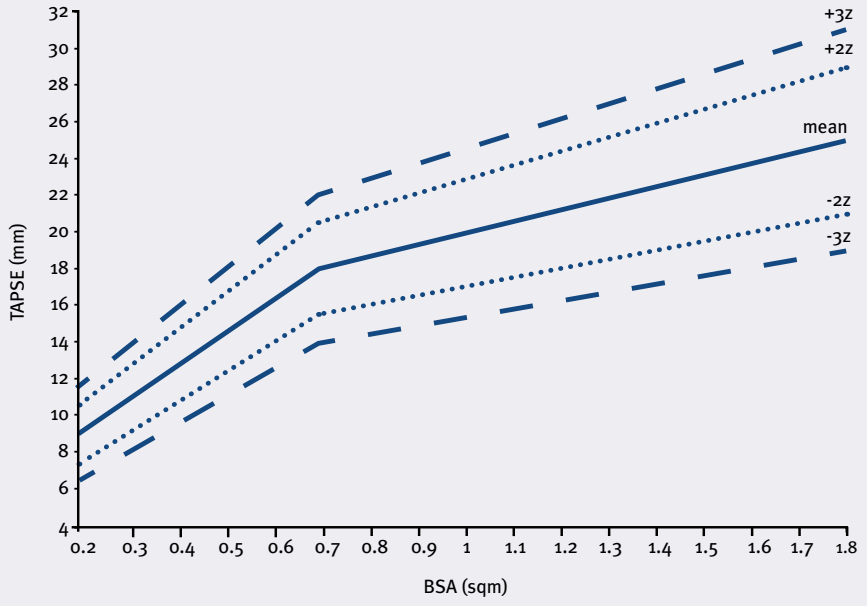

Figure 27. **Normal values for children** for tricuspid annular plane systolic excursion (TAPSE). z, standard deviation.
Schulze-Neick 2010, modified after Koestenberger JASE 2009 [52]

Pulmonary Hypertension Echocardiographic Protocol

Echocardiography Reporting

Regardless of the clinical indications for performing an echocardiogram, the report should include measurements, descriptions of all valves, the proximal great arteries, the heart chambers, the pericardium and Doppler findings, as well as conclusions.

Where pulmonary hypertension is the referral indication or the incidental echocardiogram finding, particular emphasis should be placed on not only pulmonary pressures but also on right heart chamber size and function and any findings indicating any secondary cause (left ventricular dysfunction, left heart valve disease or congenital heart disease, etc). Where pulmonary hypertension is confirmed, the report should also include the various parameters, described in the protocol, that provide important prognostic information (right atrial volume index, inferior vena cava diameter, eccentricity index, presence of pericardial effusion, etc).

The primary indicator of raised pulmonary pressure in echocardiography is the right ventricular systolic pressure derived from the tricuspid regurgitant velocity. Measurement of a low peak tricuspid regurgitant velocity in the presence of a clearly pressure loaded ventricle or reduced outflow tract acceleration time should be viewed critically. Consideration should be given as to whether optimal alignment of the tricuspid regurgitant jet was obtained or where an indistinct spectral profile was obtained the peak velocity has been underestimated. In the presence of severe (free-flow) tricuspid regurgitation, the Bernoulli equation is invalid and right ventricular systolic pressure is underestimated.

Evaluation of right ventricular size should not be based on only a single measurement of cavity dimension but in combination with a qualitative assessment from all right ventricular views. Any single linear measurement may be inadequate in describing the ventricle as a whole due its eccentric geometry. Trabeculations of the myocardial walls and indistinct endocardial definition of the lateral free wall may also limit the accuracy and reproducibility of linear and area measurements made from the apical four chamber view.

In the normal heart, the right ventricle is approximately one third the size of the left when assessed from parasternal views. This can be a useful ‘yard stick’ by which to judge right ventricular size in a qualitative assessment. While qualitative expressions of mild, moderate or severe ventricular dilatation are subjective, they are well established in echocardiography reporting and may have some value in concluding.

Comments on pressure and or volume-loading of the ventricle are based on the identification of septal displacement toward the left ventricle. Systolic septal displacement, resulting in an increased systolic eccentricity index, identifies pressure loading. Diastolic septal displacement, resulting in an increased diastolic eccentricity index, with significant valvular regurgitation or left-to-right shunting at the atrial level, identifies volume-loading. However, diastolic septal displacement with systolic ventricular dysfunction in the absence of left-to-right shunting at the atrial level or significant valvular regurgitation, indicates increased right ventricular diastolic pressures which should be differentiated from volume-loading.

Evaluation of ventricular function should be based on the evidence provided by the TAPSE, tricuspid annular S’ wave velocity and the MPI in conjunction with any qualitative impression from all right ventricular views. Any single parameter should be viewed critically, when it suggests a degree of ventricular dysfunction which is significantly different from other parameters and from a qualitative impression.For example, TAPSE may be ‘pseudonormalised’ in the presence of a pressure and volume-loaded ventricle. Ambiguity in defining the onset or offset of spectral Doppler velocity components from the tricuspid inflow, outflow tract or from TDI of the RV will lead to errors in measurements of time, significantly affecting the calculation of the MPI.

Any cut off value for measurements which are either diagnostic or prognostic have limited sensitivity or specificity. No measurement should be considered in isolation but in conjunction with all findings when forming an overall impression.

In the reporting of follow-up echocardiograms, emphasis should be placed on changes in right ventricular function as pulmonary pressures correlate poorly with the functional capacity or survival of patients. Reduction in pulmonary pressure may be related to deterioration of ventricular function, while increases in pressures may reflect improvement of ventricular function in response to therapy. Consequently, changes in pulmonary pressure should be interpreted in relation to changes in ventricular function. Reports should always be based on comparisons with previous echocardiographic findings.

Pulmonary Hypertension Echocardiographic Protocol

Sample Report - Adult

Standard protocol :

Aortic root is normal. Aortic valve is tricuspid with normal cusp excursion.

Pulmonary artery and branches are dilated (main pulmonary trunk: 3.6 cm, right pulmonary artery: 2.2 cm, left pulmonary artery: 1.8 m, in diameter). Pulmonary valve is structurally normal.

Right atrium is dilated (85 ml/m² in volume). Right ventricle is dilated (basal diameter: 5.9 cm) and pressure loaded with moderate to severe impairment of systolic function.

Left atrium is normal (28 ml/m² in volume). Left ventricle is normal in size with good systolic function. Type I LV diastolic dysfunction.

Doppler colour flow mapping demonstrates mild tricuspid and moderate pulmonary regurgitation. Peak TR velocity is 5.7 m/sec (PPG 131 mmHg).

IVC is normal in diameter (20 mm) with reduced respiratory collapse (RAP 10 mmHg).

Mild anterior (0.6 cm in maximum diameter) pericardial effusion.

Dedicated pulmonary hypertension protocol:

EId: 1.5, EIs: 2.4.

MPI with Tissue Doppler Imaging : 0.88

Tissue Doppler Imaging: S' wave: 8 cm/sec, E': 8.3 cm/sec, A': 16.3 cm/sec, IVRT: 110 msec.

Right ventricular free wall is hypertrophied (measured as 0.6 cm from subcostal view).

TAPSE with M-mode: 8 mm

RVOT acceleration time: 75 msec

PVR (estimated with Doppler echocardiography): 17.8 Wood units

Estimated cardiac output: 2.8 l/min

Conclusion:

Severe pulmonary hypertension.

Dilated RV with severe impairment of systolic function.

Good LV function.

When compared to the previous exam, there is no change in pulmonary pressures or in RV systolic function.

2D echo	Measurement	Normal range
LV diastolic diameter base LX	3.6 cm	3.9 – 5.3 cm
LV systolic diameter base LX	1.6 cm	2.0 – 4.0 cm
Fractional shortening base LX	0.56	0.29 – 0.37 cm
IVS diastolic thickness	0.92 cm	0.8 – 1.1 cm
LVPW diastolic thickness	0.84 cm	0.8 – 1.1 cm
LA systolic diameter LX	3.3 cm	2.7 – 3.8 cm
Aortic root diameter	2.8 cm	2.7 – 3.3 cm
Doppler		
AV peak velocity	103 cm/sec	
AV peak gradient	4.2 mmHg	
LVOT peak velocity	84.9 cm/sec	
LVOT peak gradient	2.9 mmHg	
LVOT AV vel ratio	0.83	
Mitral E point velocity	64.5 cm/sec	
Mitral A point velocity	73 cm/sec	
Mitral E/A ratio	0.88	
MV deceleration time	200 msec	
PV end-diastolic velocity	254 cm/sec	
PV peak gradient	25.8 mmHg	
TR peak velocity	573 cm/sec	
TR peak gradient	131 mmHg	

Sample Report - Paediatric

SUBCOSTAL VIEW			
IVC diameter during sniff in mm		max	min
Interatrial communication with direction shunt	ASD/PFO/no	size	L-R-bidir
APICAL 4 CHAMBER VIEW	**RIGHT**		**LEFT**
ATRIAL			
Area (cm²)			
Ratio (R:L area)			
IAS bulging into LA		not/+/++/+++	
VENTRICULAR			
Area (cm²)			
Ratio (R:L area)			
Hypertrophied:	not /+/++/+++		not /+/++/+++
Dilated:	not /+/++/+++		not /+/++/+++
Red. Function:	not /+/++/+++		not /+/++/+++
IVS bulging into LV		not /+/++/+++	
Doppler-Measurements			
ATRIOVENTRICULAR VALVES	**TRICUSPID**		**MITRAL**
Inflow pattern	E/A/EAratio		E/A/EAratio
Stenosis	mi/md/sv; m/sec, mmHg		mi/md/sv; m/sec, mmHg
Regurgitation	mi/md/sv; m/sec, mmHg		mi/md/sv; m/sec, mmHg
SEMILUNAR VALVE	**PULMONARY**		**AORTIC**
Stenosis mild/mod/sev; m/sec, mmHg	mi/md/sv; m/sec, mmHg		mi/md/sv; m/sec, mmHg
Regurgitation mild/mod/sev; m/sec, mmHg	mi/md/sv; m/sec, mmHg		mi/md/sv; m/sec, mmHg

Pulmonary Hypertension Echocardiographic Protocol

M-MODE MEASUREMENTS	RIGHT		LEFT
APSE (mm)			
Valve Ring to Apex distance (mm)			
Tissue Doppler Recordings for later Analysis			
LONG AXIS			
LVEDD, LVESD (), FS %			
Ao (mm), LA (mm), ratio			
SHORT AXIS			
LV eccentricity index			
Diameters			
Aorta (ST junction)			
PA (ST junction)			
PA (prebifurcation)			
RPA(postbifurcation)			
LPA(postbifurcation)			
Doppler-Measurements			
Pulmonary Valve			
Stenosis mild/mod/sev; m/sec, mmHg	mi/md/sv; m/sec, mmHg		mi/md/sv; m/sec, mmHg
Regurgitation mild/mod/sev; m/sec, mmHg	mi/md/sv; m/sec, mmHg		mi/md/sv; m/sec, mmHg
OTHER Findings & Comments			
Left SVC			
Coronary Sinus			
Pulmonary Veins			
PDA			
Coarctation			

Pulmonary Hypertension Echocardiographic Protocol

References

1. McQuillan BM, Picard MH, Leavitt M et al. Clinical correlates and reference intervals for pulmonary artery systolic pressure among echocardiographically normal subjects. *Circulation* 2001;**104**:2797-802.

2. Galie N et al. The task force for the diagnosis and treatment of pulmonary hypertension for the European Society of Cardiology (ESC) and the EuropeanRespiratory Society (ERS), endorsed by the International Society of Heart and Lung Transplantation (ISHLT). European Heart Journal 2009; **30**: 2493–2537.

3. Consensus statement on the management of pulmonary hypertension in clinical practice in the UK and Ireland. *Heart* 2008;**94 Suppl** 1:i1-41.

4. Consensus statement on the management of pulmonary hypertension in clinical practice in the UK and Ireland. *Thorax* 2008;**63 Suppl 2**:ii1-ii41.

5. Vahanian A, Baumgartner H, Bax J et al. Guidelines on the management of valvular heart disease: The Task Force on the Management of Valvular Heart Disease of the European Society of Cardiology. *Eur Heart J* 2007;**28**:230-68.

6. Yoshida K, Yoshikawa J, Shakudo M et al. Color Doppler evaluation of valvular regurgitation in normal subjects. *Circulation* 1988;**78**:840-7.

7. Foale R, Nihoyannopoulos P, McKenna W et al. Echocardiographic measurement of the normal adult right ventricle. *Br Heart J* 1986;**56**:33-44.

8. Kitabatake A, Inoue M, Asao M et al. Noninvasive evaluation of pulmonary hypertension by a pulsed Doppler technique. *Circulation* 1983;**68**:302-9.

9. Lang RM, Bierig M, Devereux RB et al. Recommendations for chamber quantification: a report from the American Society of Echocardiography's Guidelines and Standards Committee and the Chamber Quantification Writing Group, developed in conjunction with the European Association of Echocardiography, a branch of the European Society of Cardiology. *J Am Soc Echocardiogr* 2005;**18**:1440-63.

10. Maeba H, Nakatani S, Sugawara M *et al*. Different time course of changes in tricuspid regurgitant pressure gradient and pulmonary artery flow acceleration after pulmonary thromboendarterectomy: implications for discordant recovery of pulmonary artery pressure and compliance. *Circ J* 2007;**71**:1771-5.

11. Forfia PR, Fisher MR, Mathai SC et al. Tricuspid annular displacement predicts survival in pulmonary hypertension. *Am J Respir Crit Care Med* 2006;**174**:1034-41.

12. Kaul S, Tei C, Hopkins JM et al. Assessment of right ventricular function using two-dimensional echocardiography. *Am Heart J* 1984;**107**:526-31.

13. Lee CY, Chang SM, Hsiao SH et al. Right heart function and scleroderma: insights from tricuspid annular plane systolic excursion. *Echocardiography* 2007;**24**:118-25.

14. Olson JM, Samad BA, Alam M. Prognostic value of pulse-wave tissue Doppler parameters in patients with systolic heart failure. *Am J Cardiol* 2008;**102**:722-5.

15. Abbas A, Lester S, Moreno FC et al. Noninvasive assessment of right atrial pressure using Doppler tissue imaging. *J Am Soc Echocardiogr* 2004;**17**:1155-60.

16. Santamore WP, Dell'Italia LJ. Ventricular interdependence: significant left ventricular contributions to right ventricular systolic function. *Prog Cardiovasc Dis* 1998;**40**:289-308.

17. Stein PD, Sabbah HN, Anbe DT et al. Performance of the failing and nonfailing right ventricle of patients with pulmonary hypertension. *Am J Cardiol* 1979;**44**:1050-5.

18. Schnittger I, Gordon EP, Fitzgerald PJ et al. Standardized intracardiac measurements of two-dimensional echocardiography. *J Am Coll Cardiol* 1983;**2**:934-8.

19. Wang Y, Gutman JM, Heilbron D et al. Atrial volume in a normal adult population by two-dimensional echocardiography. *Chest* 1984;**86**:595-601.

20. Dujardin KS, Tei C, Yeo TC *et al*. Prognostic value of a Doppler index combining systolic and diastolic performance in idiopathic-dilated cardiomyopathy. *Am J Cardiol* 1998;**82**:1071-6.

21. Tei C, Dujardin KS, Hodge DO *et al*. Doppler echocardiographic index for assessment of global right ventricular function. *J Am Soc Echocardiogr* 1996;**9**:838-47.

22. Yeo TC, Dujardin KS, Tei C *et al*. Value of a Doppler-derived index combining systolic and diastolic time intervals in predicting outcome in primary pulmonary hypertension. *Am J Cardiol* 1998;**81**:1157-61.

23. Alam M, Wardell J, Andersson E *et al*. Characteristics of mitral and tricuspid annular velocities determined by pulsed wave Doppler tissue imaging in healthy subjects. *J Am Soc Echocardiogr* 1999;**12**:618-28.

24. Feneley M, Gavaghan T. Paradoxical and pseudoparadoxical interventricular septal motion in patients with right ventricular volume overload. *Circulation* 1986;**74**:230-8.

25. Ryan T, Petrovic O, Dillon JC *et al*. An echocardiographic index for separation of right ventricular volume and pressure overload. *J Am Coll Cardiol* 1985;**5**:918-27.

26. Abbas AE, Fortuin FD, Schiller NB *et al*. A simple method for noninvasive estimation of pulmonary vascular resistance. *J Am Coll Cardiol* 2003;**41**:1021-7.

27. Scapellato F, Temporelli PL, Eleuteri E *et al*. Accurate noninvasive estimation of pulmonary vascular resistance by Doppler echocardiography in patients with chronic failure heart failure. *J Am Coll Cardiol* 2001;**37**:1813-9.

28. Hammarstrom E, Wranne B, Pinto FJ *et al*. Tricuspid annular motion. *J Am Soc Echocardiogr* 1991;**4**:131-9.

29. Lopez-Candales A, Dohi K, Rajagopalan N *et al*. Defining normal variables of right ventricular size and function in pulmonary hypertension: an echocardiographic study. *Postgrad Med J* 2008;**84**:40-5.

30. Haddad F, Hunt SA, Rosenthal DN *et al*. Right ventricular function in cardiovascular disease, part I: Anatomy, physiology, aging, and functional assessment of the right ventricle. *Circulation* 2008;**117**:1436-48.

31. Haddad F, Doyle R, Murphy DJ *et al*. Right ventricular function in cardiovascular disease, part II: pathophysiology, clinical importance, and management of right ventricular failure. *Circulation* 2008;**117**:1717-31.

32. Bogaard HJ, Abe K, Vonk Noordegraaf A *et al*. The right ventricle under pressure: cellular and molecular mechanisms of right-heart failure in pulmonary hypertension. *Chest* 2009;**135**:794-804.

33. Anavekar NS, Skali H, Bourgoun M *et al*. Usefulness of right ventricular fractional area change to predict death, heart failure, and stroke following myocardial infarction (from the VALIANT ECHO Study). *Am J Cardiol* 2008;**101**:607-12.

34. Wang J, Prakasa K, Bomma C *et al*. Comparison of novel echocardiographic parameters of right ventricular function with ejection fraction by cardiac magnetic resonance. *J Am Soc Echocardiogr* 2007;**20**:1058-64.

35. Meluzin J, Spinarova L, Bakala J *et al*. Pulsed Doppler tissue imaging of the velocity of tricuspid annular systolic motion; a new, rapid, and non-invasive method of evaluating right ventricular systolic function. *Eur Heart J* 2001;**22**:340-8.

36. Ilercil A, O'Grady MJ, Roman MJ *et al*. Reference values for echocardiographic measurements in urban and rural populations of differing ethnicity: the Strong Heart Study. *J Am Soc Echocardiogr* 2001;**14**:601-11.

37. Schiller NB, Shah PM, Crawford M *et al*. Recommendations for quantitation of the left ventricle by two-dimensional echocardiography. American Society of Echocardiography Committee on Standards, Subcommittee on Quantitation of Two-Dimensional Echocardiograms. *J Am Soc Echocardiogr* 1989;**2**:358-67.

Pulmonary Hypertension Echocardiographic Protocol

38. Kitzman DW, Scholz DG, Hagen PT et al. Age-related changes in normal human hearts during the first 10 decades of life. Part II (Maturity): A quantitative anatomic study of 765 specimens from subjects 20 to 99 years old. Mayo Clin Proc 1988;**63**:137-46.

39. Triulzi M, Gillam LD, Gentile F et al. Normal Adult Cross-Sectional Echocardiographic Values: Linear Dimensions and Chamber Areas Echocardiography 1984;**1**:403-26.

40. Appleton CP, Firstenberg MS, Garcia MJ et al. The echo-Doppler evaluation of left ventricular diastolic function. A current perspective. Cardiol Clin 2000;**18**:513-46, ix.

41. Hatle L, Angelsen B. Doppler Ultrasound in Cardiology. 1985:93.

42. Mukerjee D, St George D, Knight C et al. Echocardiography and pulmonary function as screening tests for pulmonary arterial hypertension in systemic sclerosis. Rheumatology (Oxford) 2004;**43**:461-6.

43. Fisher MR, Forfia PR, Chamera E et al. Accuracy of Doppler Echocardiography in the Hemodynamic Assessment of Pulmonary Hypertension. Am J Respir Crit Care Med 2009;**179**:615-21.

44. Nath J, Foster E, Heidenreich PA. Impact of tricuspid regurgitation on long-term survival. J Am Coll Cardiol 2004;**43**:405-9.

45. Zoghbi WA, Enriquez-Sarano M, Foster E et al. Recommendations for evaluation of the severity of native valvular regurgitation with two-dimensional and Doppler echocardiography. J Am Soc Echocardiogr 2003;**16**:777-802.

46. Galie N, Hinderliter AL, Torbicki A et al. Effects of the oral endothelin-receptor antagonist bosentan on echocardiographic and doppler measures in patients with pulmonary arterial hypertension. J Am Coll Cardiol 2003;**41**:1380-6.

47. Sitbon O, Humbert M, Jais X et al. Long-term response to calcium channel blockers in idiopathic pulmonary arterial hypertension. Circulation 2005;**111**:3105-11.

48. Recommendations on the management of pulmonary hypertension in clinical practice. Heart 2001;**86 Suppl 1**:I1-13.

49. Raymond RJ, Hinderliter AL, Willis PW et al. Echocardiographic predictors of adverse outcomes in primary pulmonary hypertension. J Am Coll Cardiol 2002;**39**:1214-9.

50. Ghio S, Klersy C, Magrini G et al. Prognostic relevance of the echocardiographic assessment of right ventricular function in patients with idiopathic pulmonary arterial hypertension. Int J Cardiol 2008.

51. Blanchard DG, Malouf PJ, Gurudevan SV et al. Utility of right ventricular Tei index in the noninvasive evaluation of chronic thromboembolic pulmonary hypertension before and after pulmonary thromboendarterectomy. JACC Cardiovasc Imaging 2009;**2**:143-9.

52. Koestenbeger M et al. Right ventricular function in infants, children and adolescents: reference values of the Tricuspid Annular Plane Systolic Excursion (TAPSE) in 640 healthy patients and calculation of z score variables. J Am Soc Echocard 2009; **22 (6)**: 715-19

National Pulmonary Hypertension Centres of Britain and Ireland

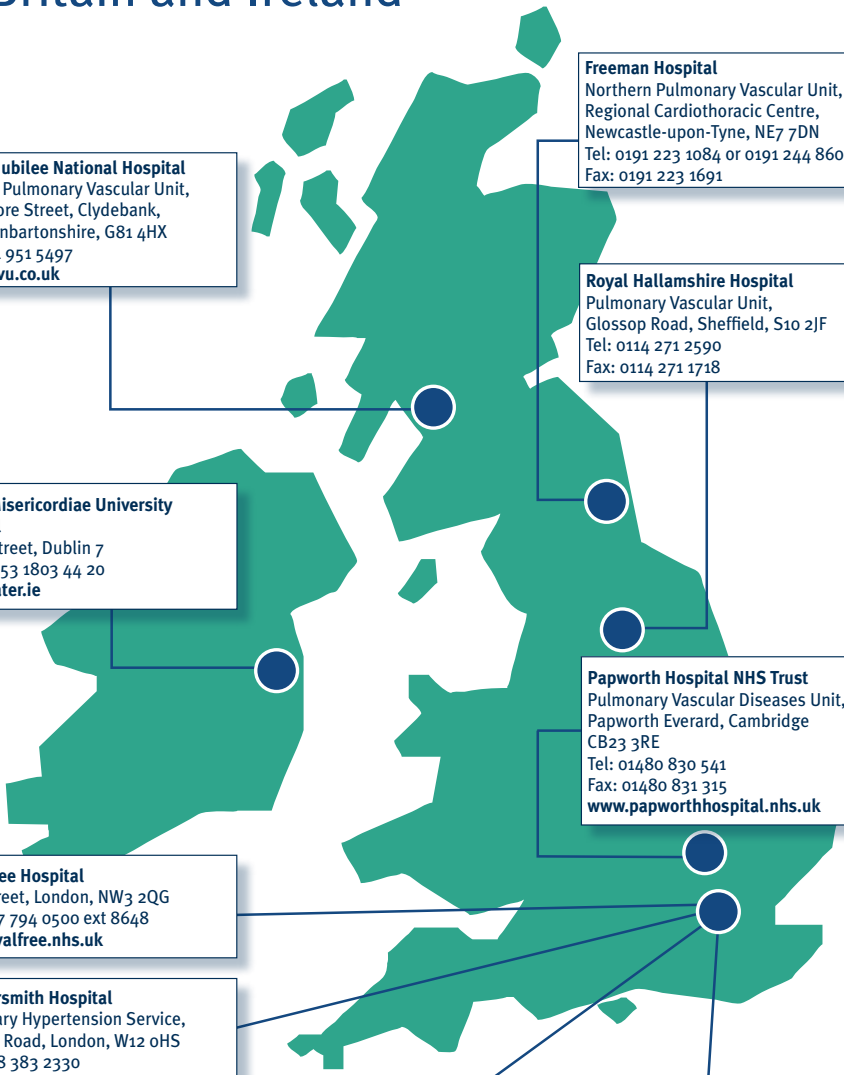

Freeman Hospital
Northern Pulmonary Vascular Unit,
Regional Cardiothoracic Centre,
Newcastle-upon-Tyne, NE7 7DN
Tel: 0191 223 1084 or 0191 244 8608
Fax: 0191 223 1691

Golden Jubilee National Hospital
Scottish Pulmonary Vascular Unit,
Beardmore Street, Clydebank,
West Dunbartonshire, G81 4HX
Tel: 0141 951 5497
www.spvu.co.uk

Royal Hallamshire Hospital
Pulmonary Vascular Unit,
Glossop Road, Sheffield, S10 2JF
Tel: 0114 271 2590
Fax: 0114 271 1718

Mater Misericordiae University Hospital
Eccles Street, Dublin 7
Tel: 00 353 1803 44 20
www.mater.ie

Papworth Hospital NHS Trust
Pulmonary Vascular Diseases Unit,
Papworth Everard, Cambridge
CB23 3RE
Tel: 01480 830 541
Fax: 01480 831 315
www.papworthhospital.nhs.uk

Royal Free Hospital
Pond Street, London, NW3 2QG
Tel: 0207 794 0500 ext 8648
www.royalfree.nhs.uk

Hammersmith Hospital
Pulmonary Hypertension Service,
Du Cane Road, London, W12 0HS
Tel: 0208 383 2330
Fax: 0208 383 2331
www.pulmonary-hypertension.org.uk

Great Ormond Street Hospital
UK Service for Pulmonary Hypertension
in Children. London, WC1N 3JH
Tel: 0207 405 9200
ext 1005, 1007, 8495
www.sphch.co.uk

Royal Brompton
Pulmonary Hypertension and Adult
Congenital Heart Centre, Sydney Street,
London SW3 6NP
Tel: 0207 351 8362
Fax: 0207 351 8629
www.rbht.nhs.uk